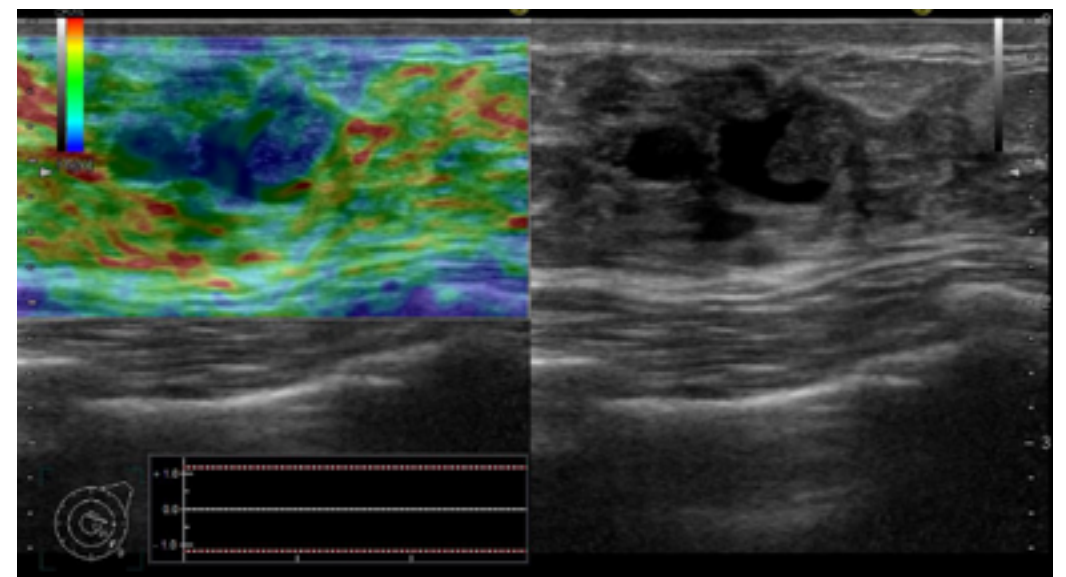
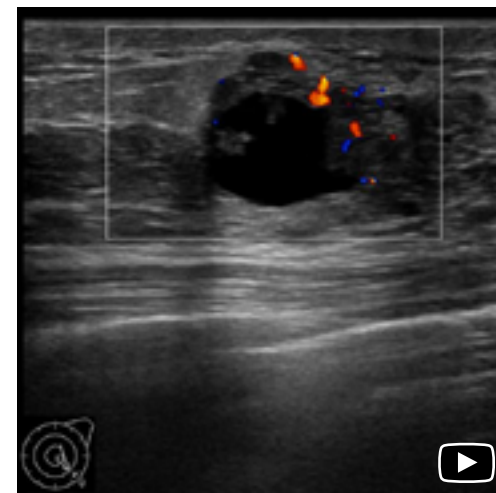
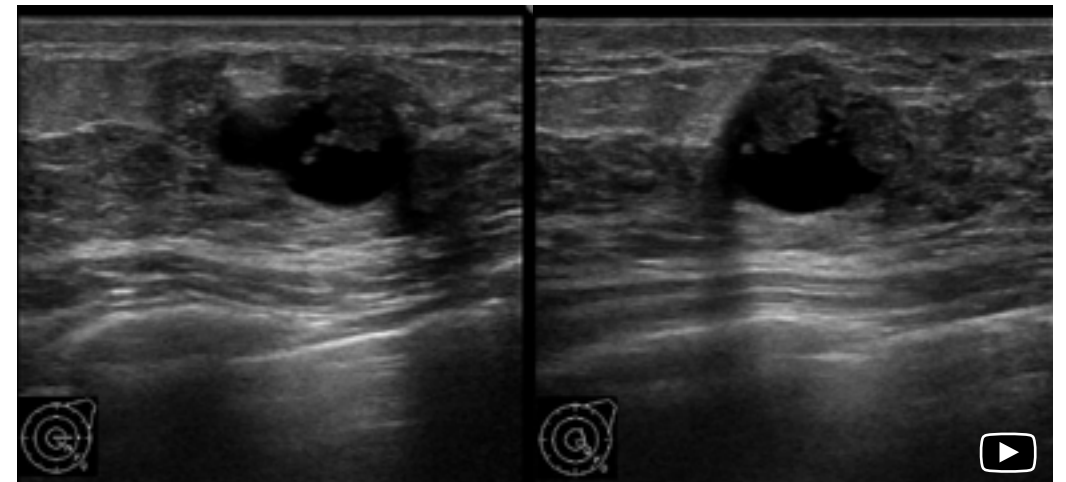
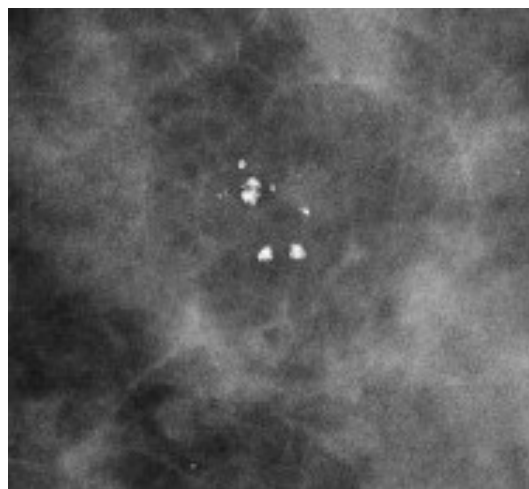
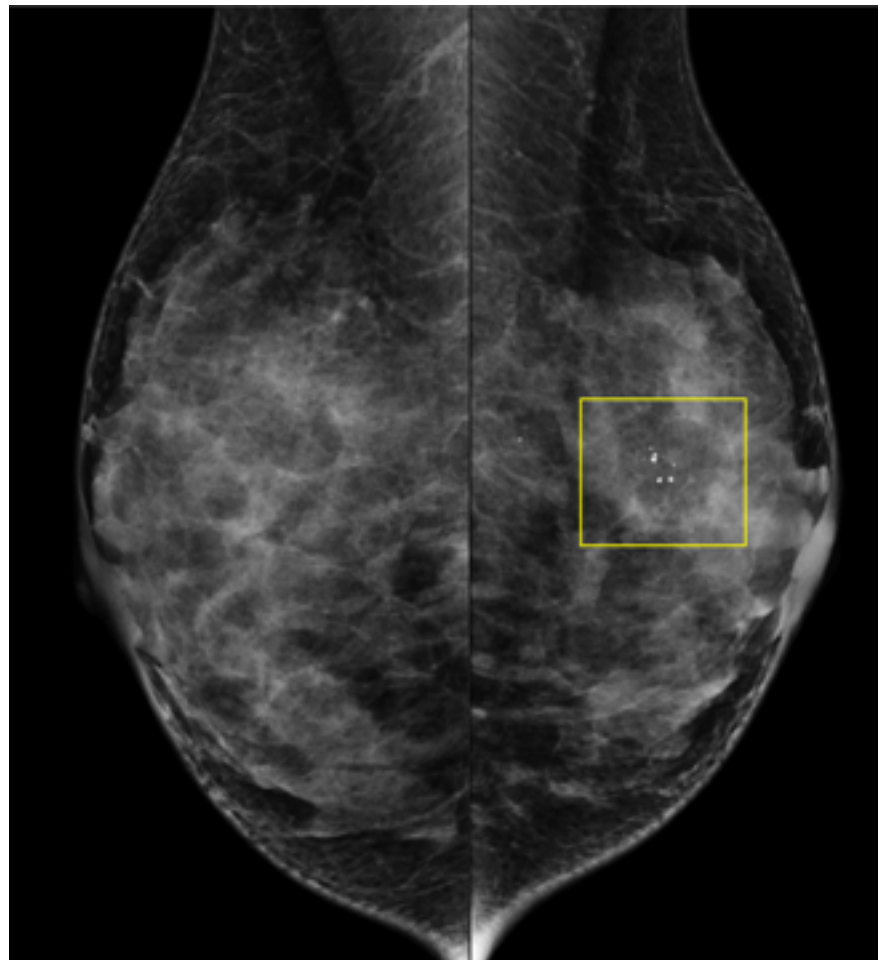
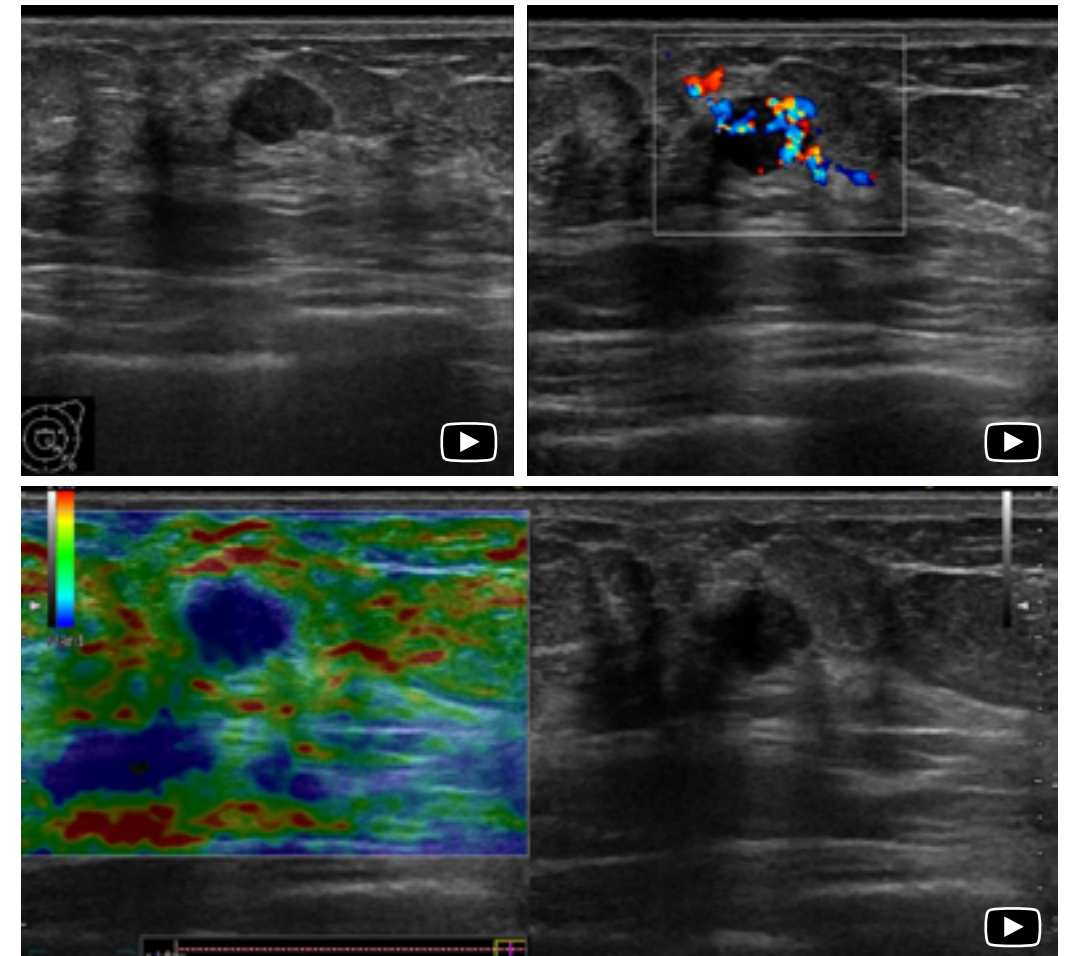
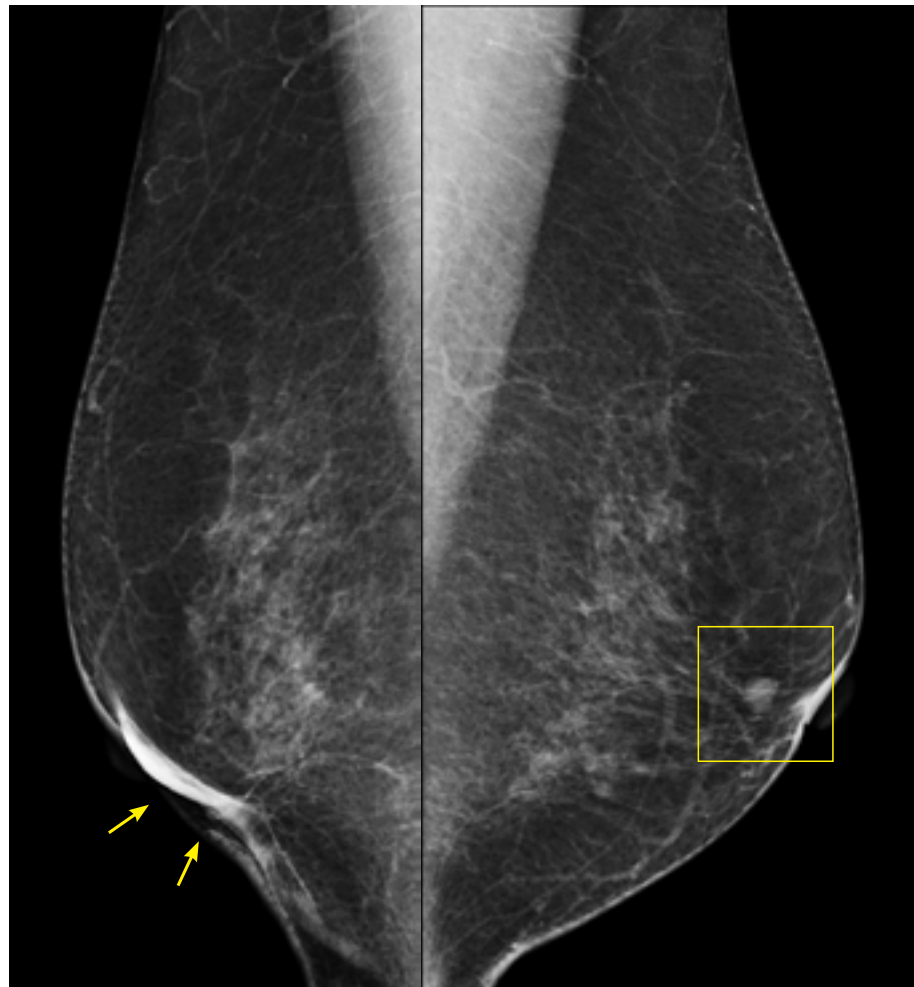


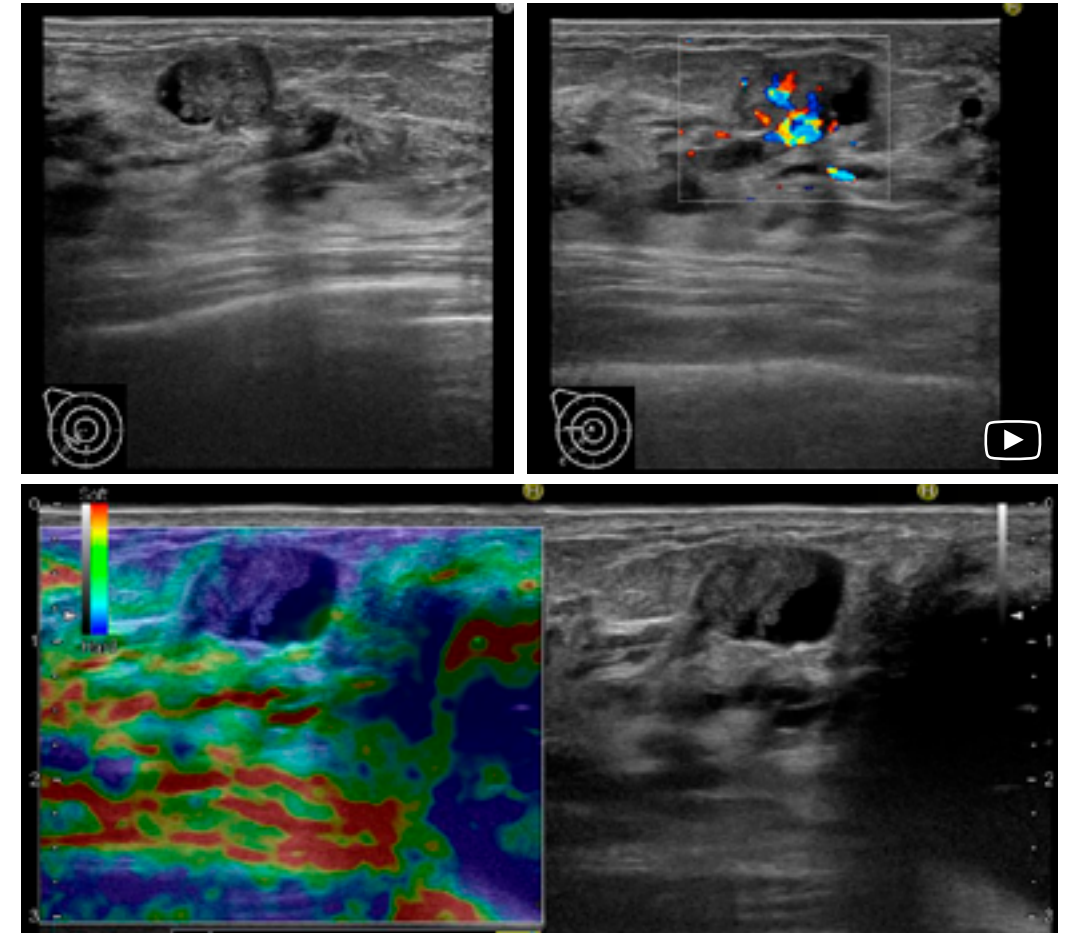
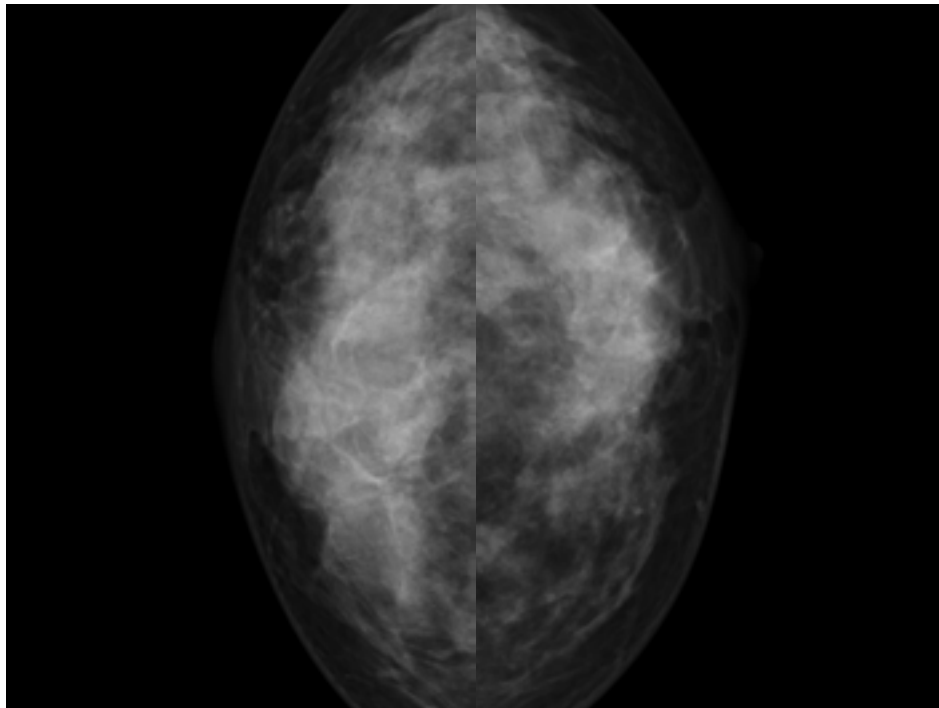
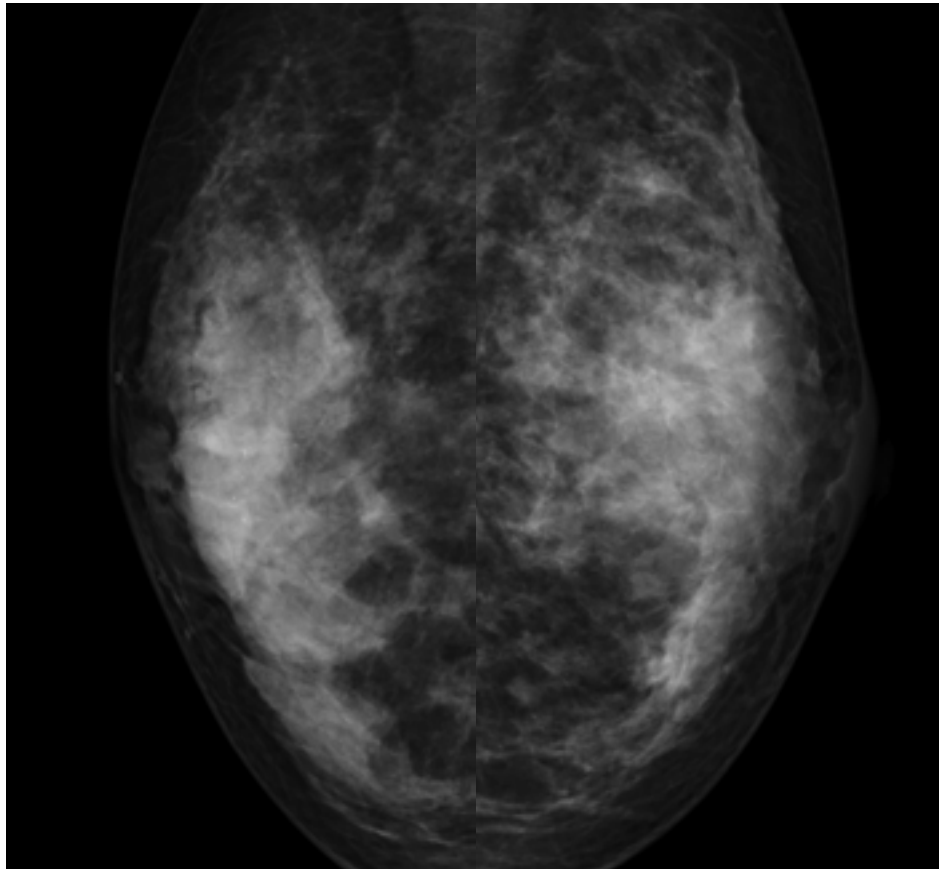
症例 11 (40歳代)



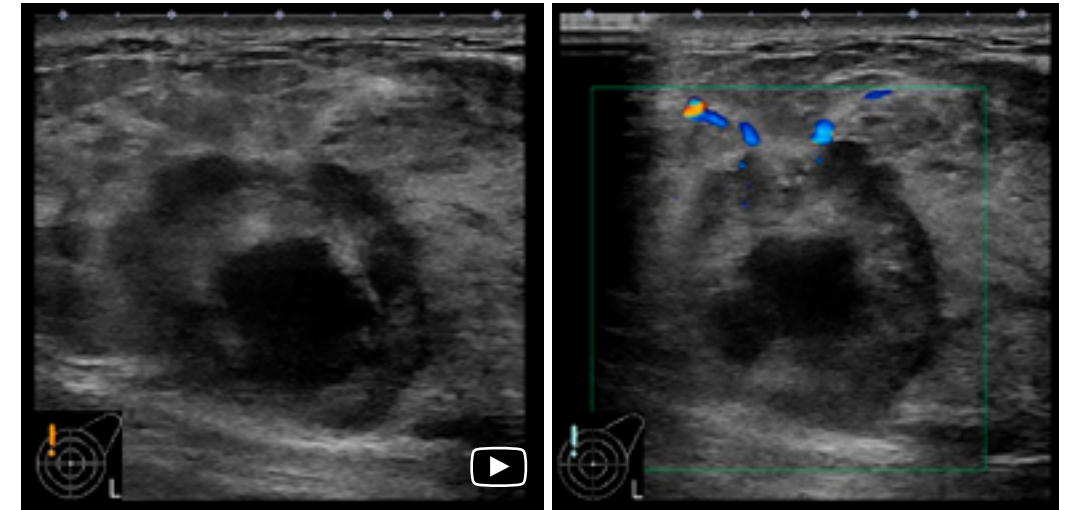
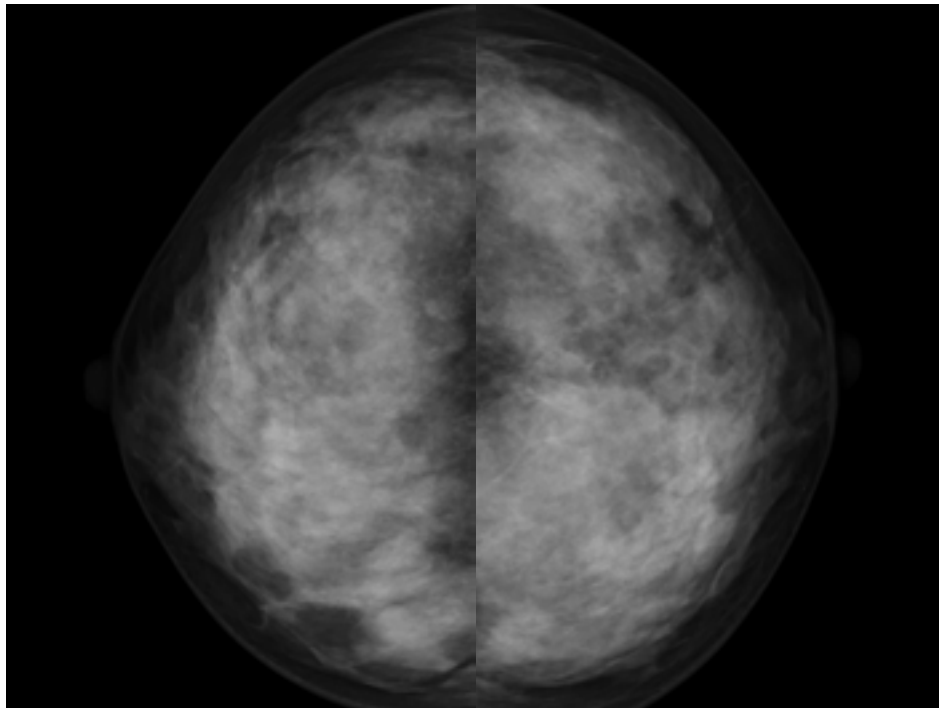
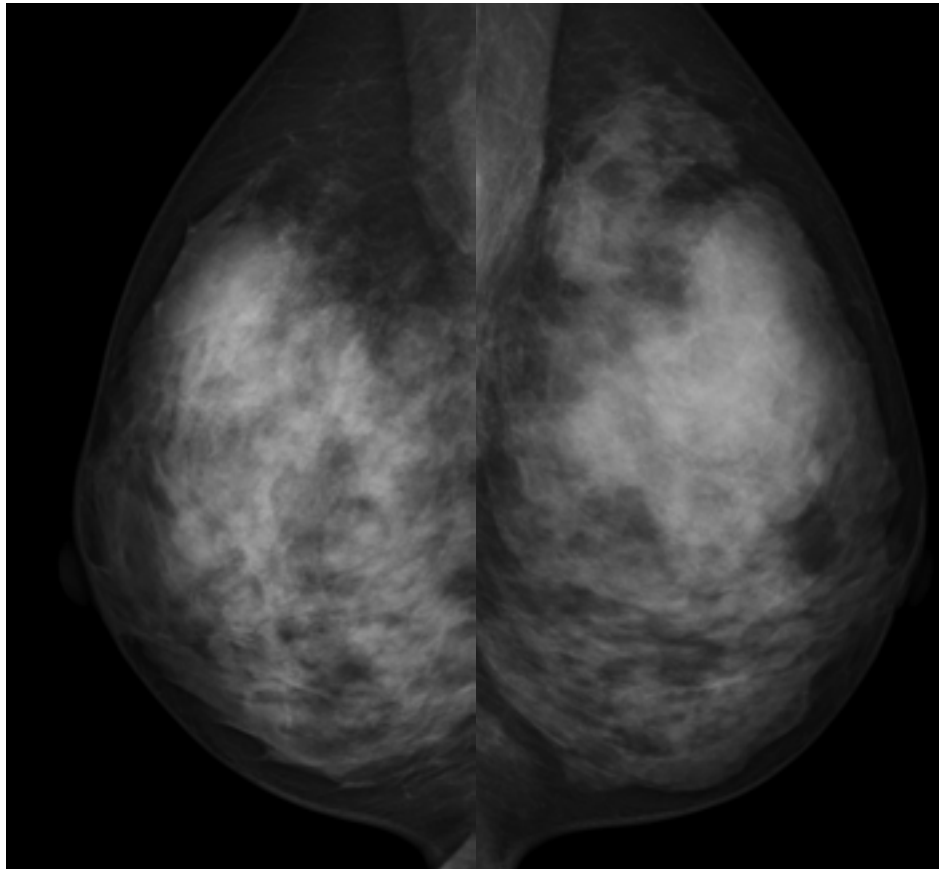
症例 12 (60歳代)



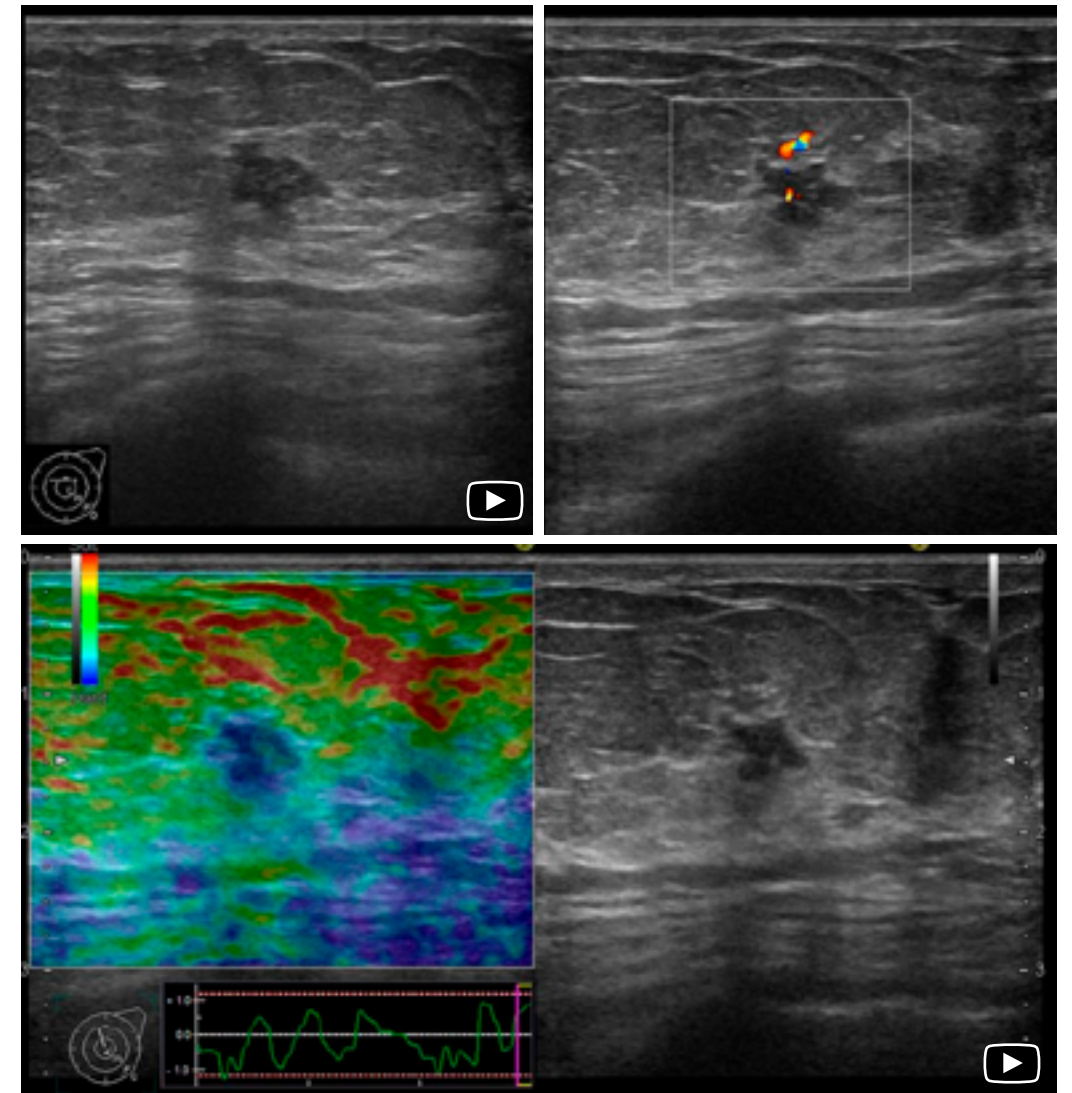
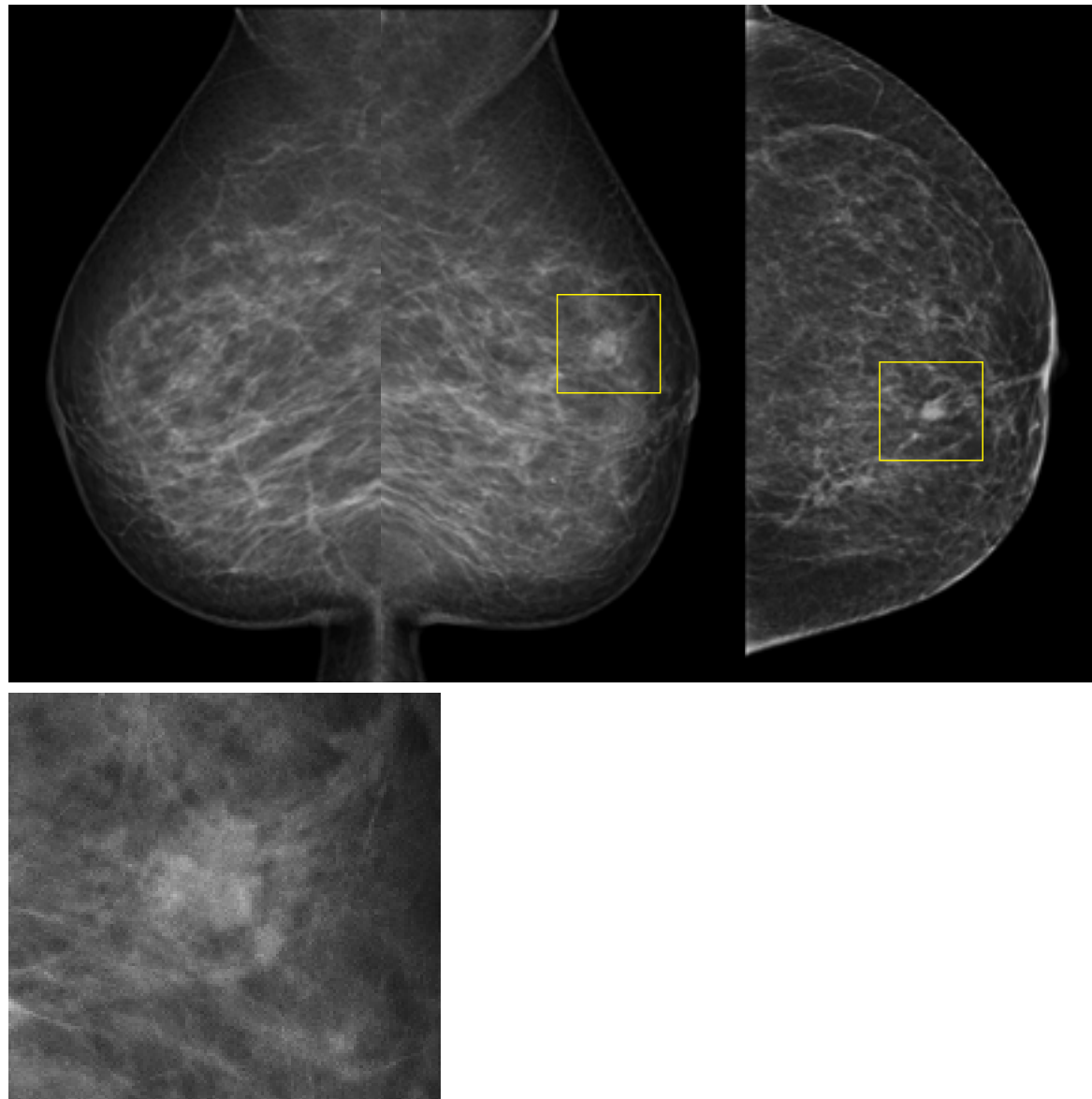
症例 13 (40歳代)



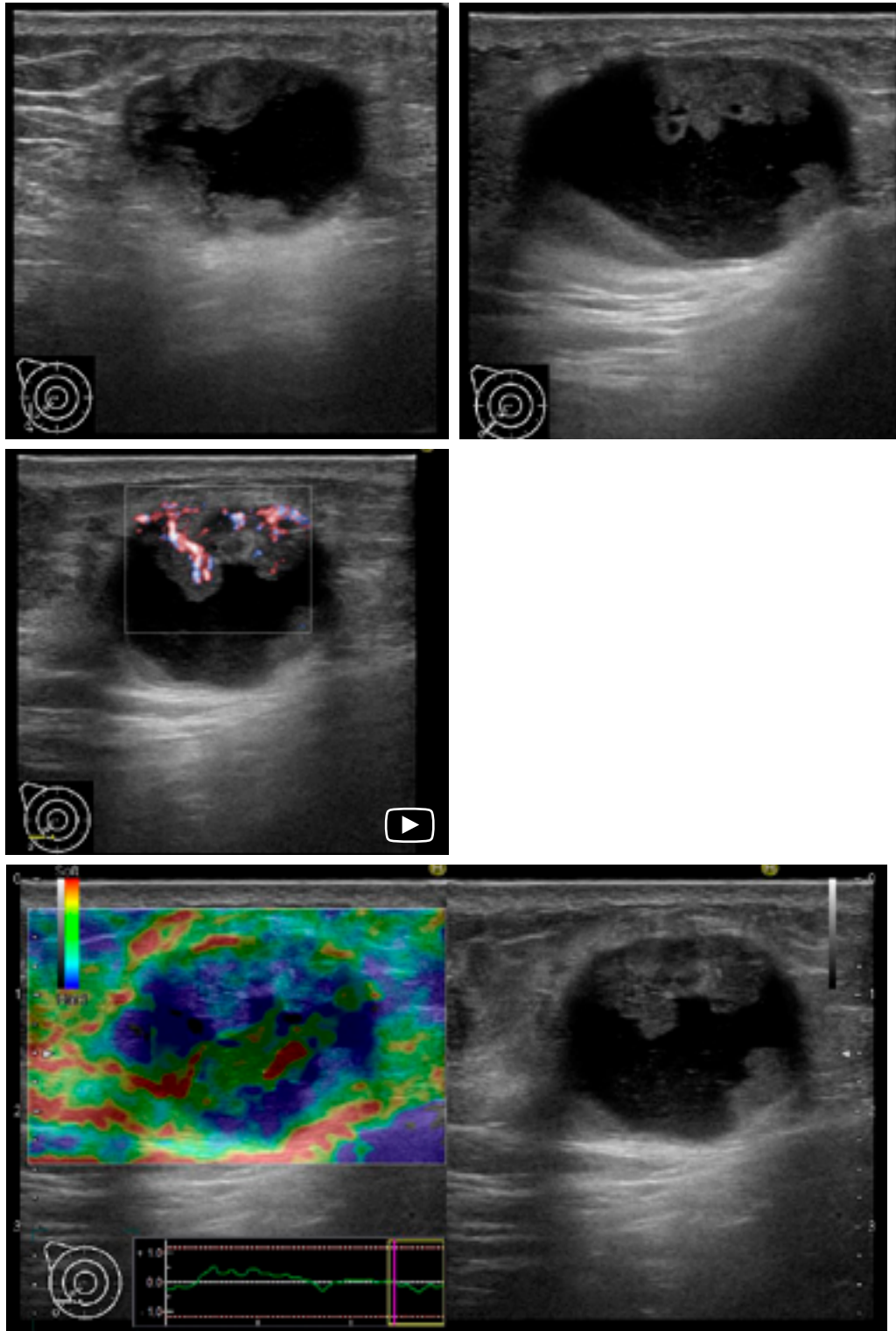
症例 14 (40歳代)



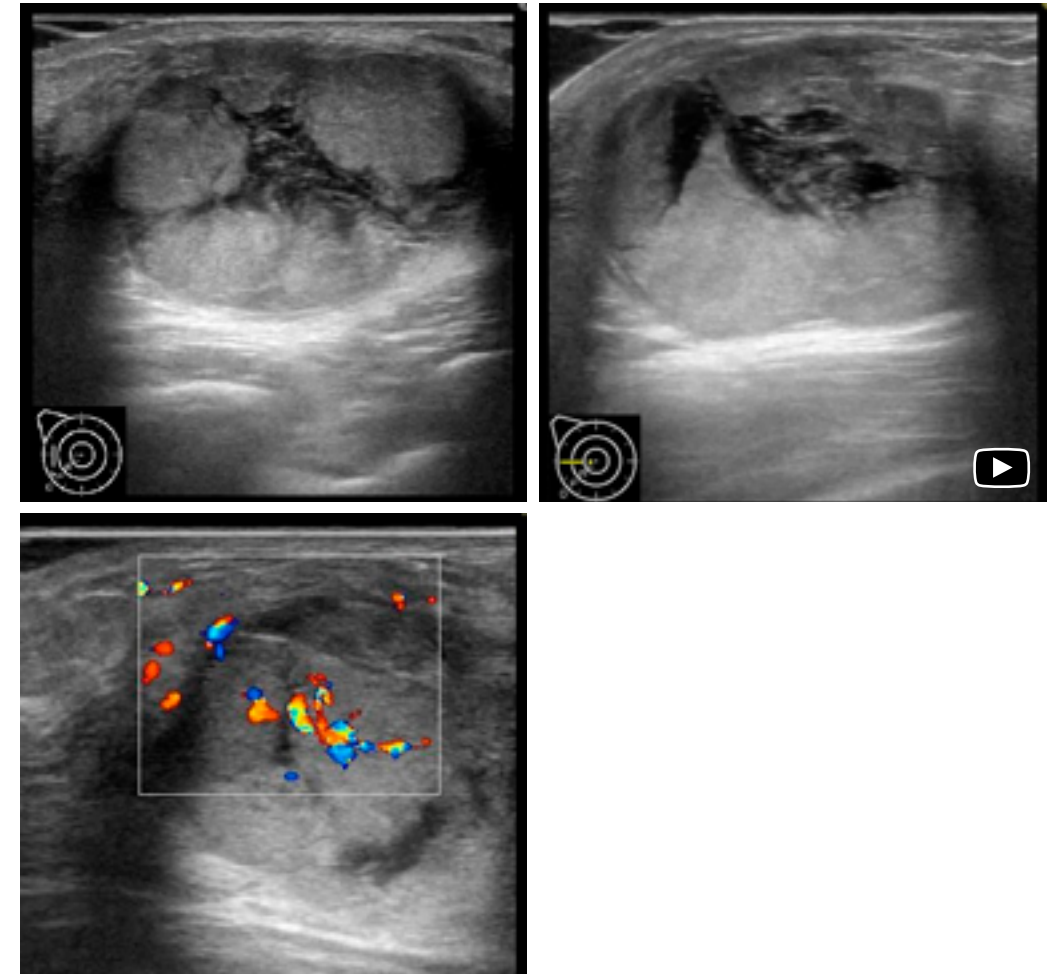
症例 15 (60歳代)



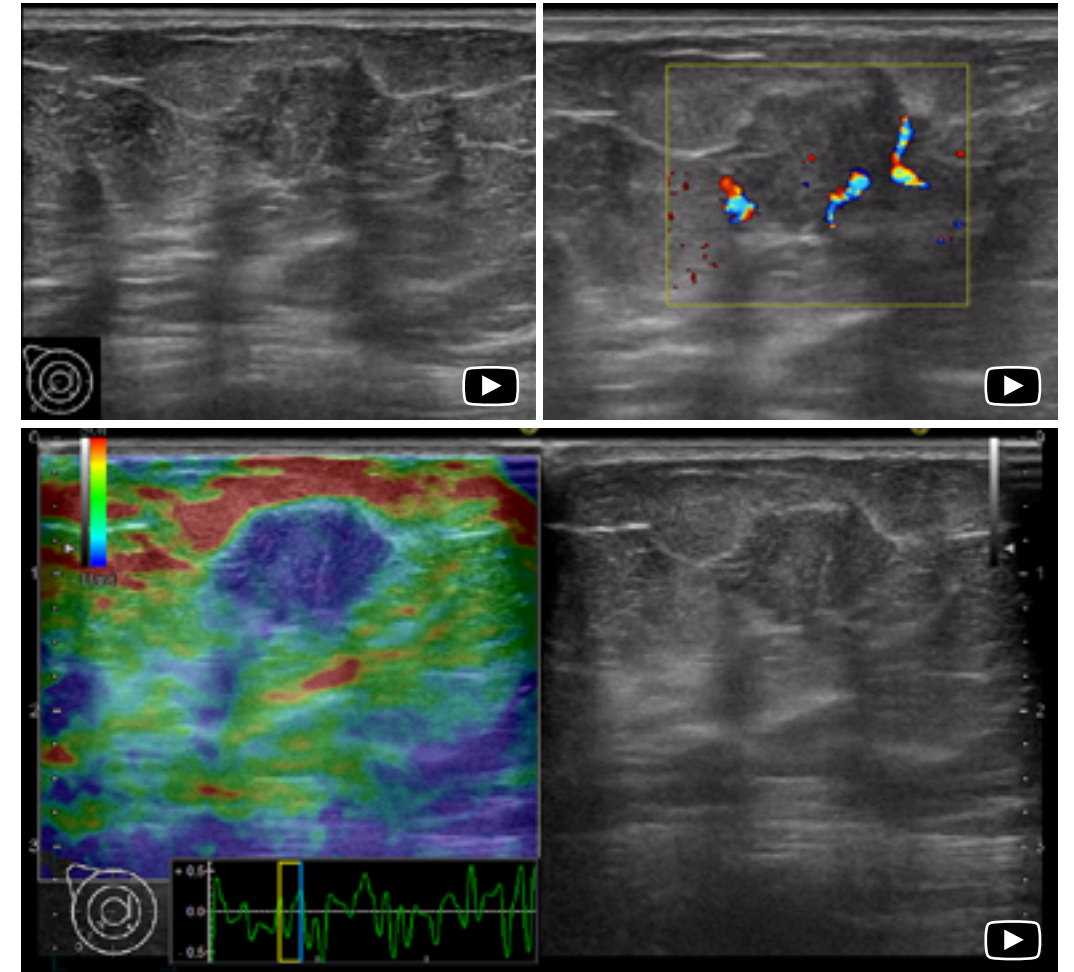
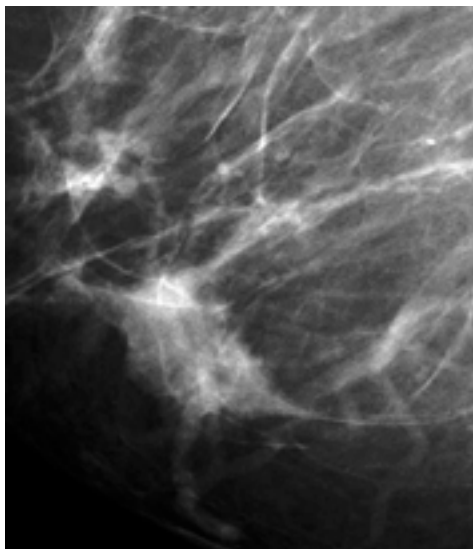
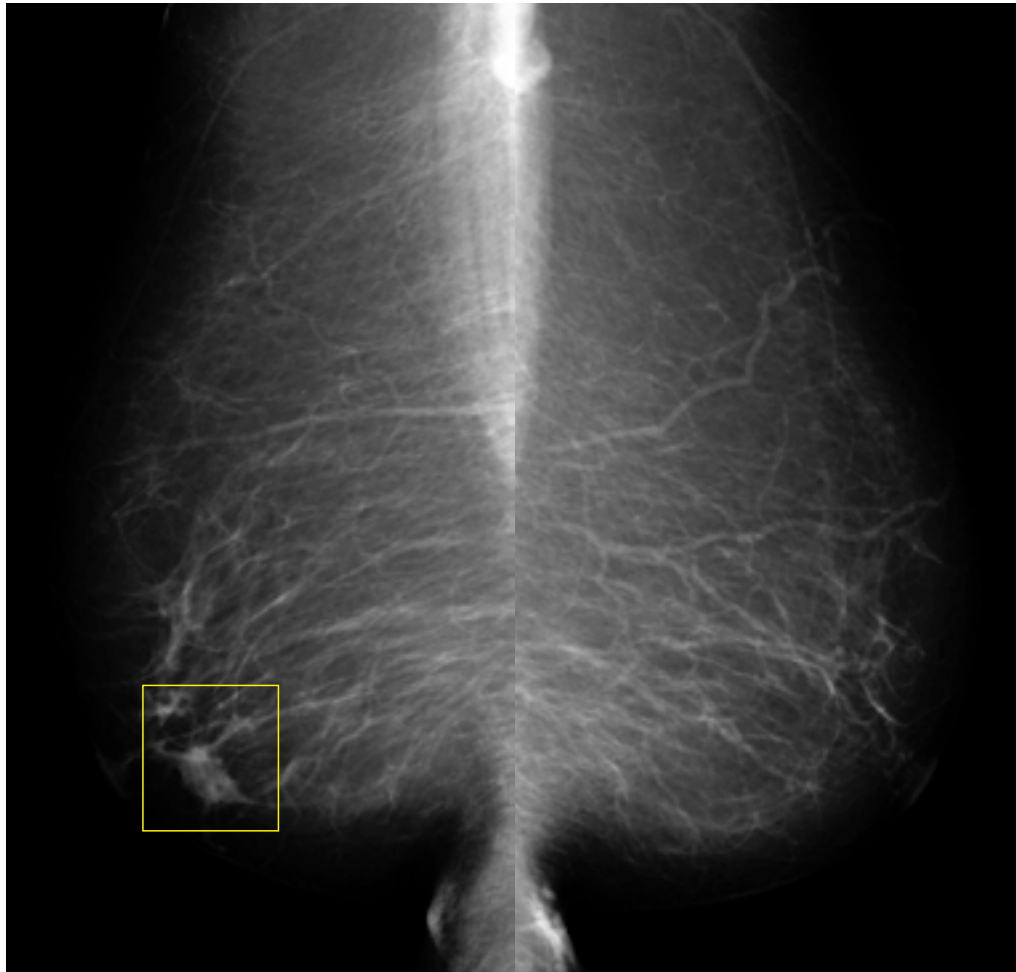
症例 16 (50歳代)



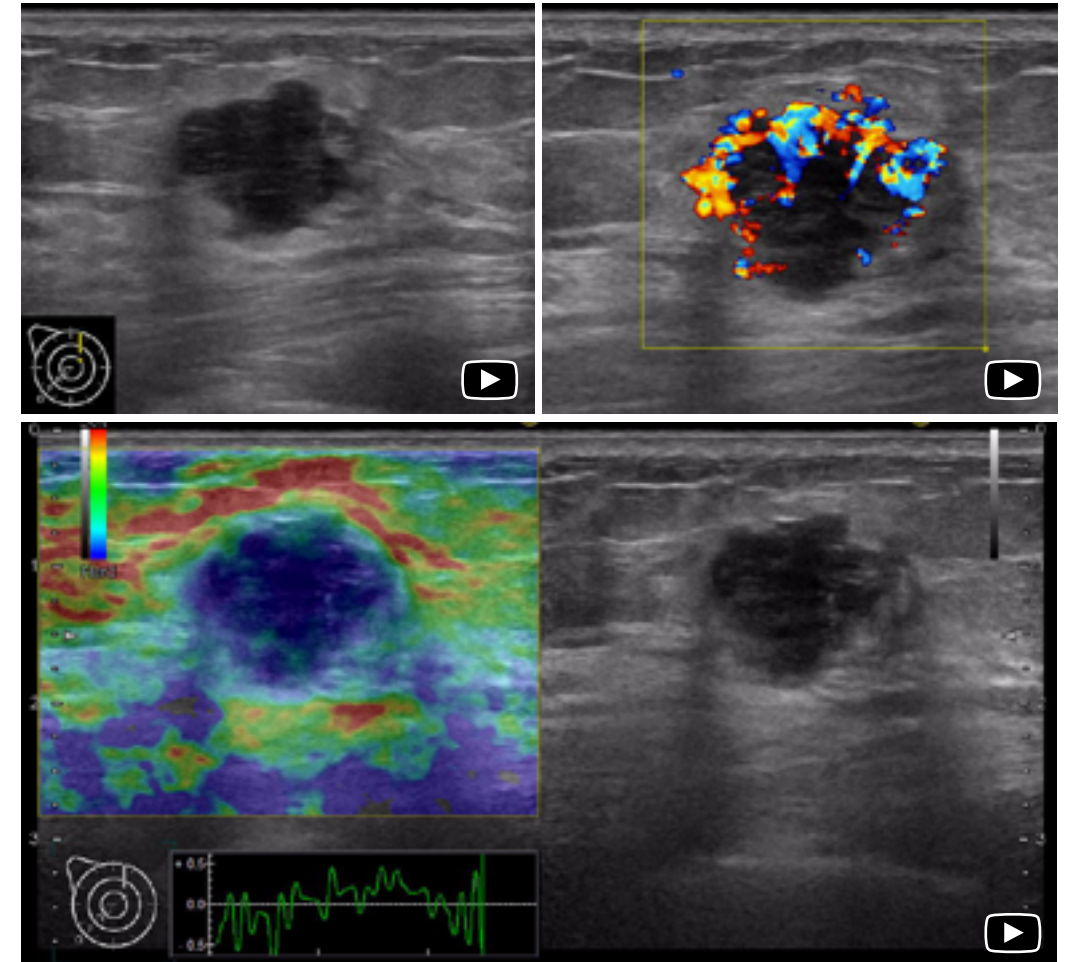
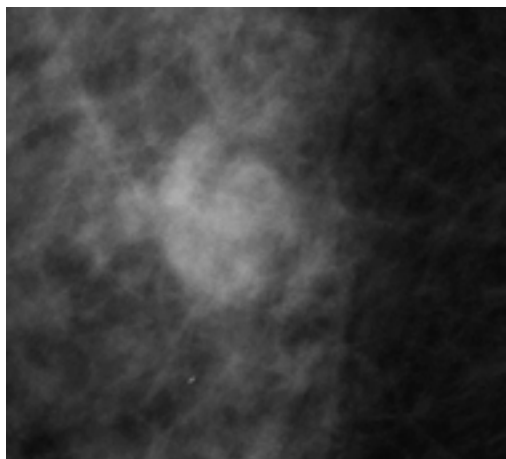
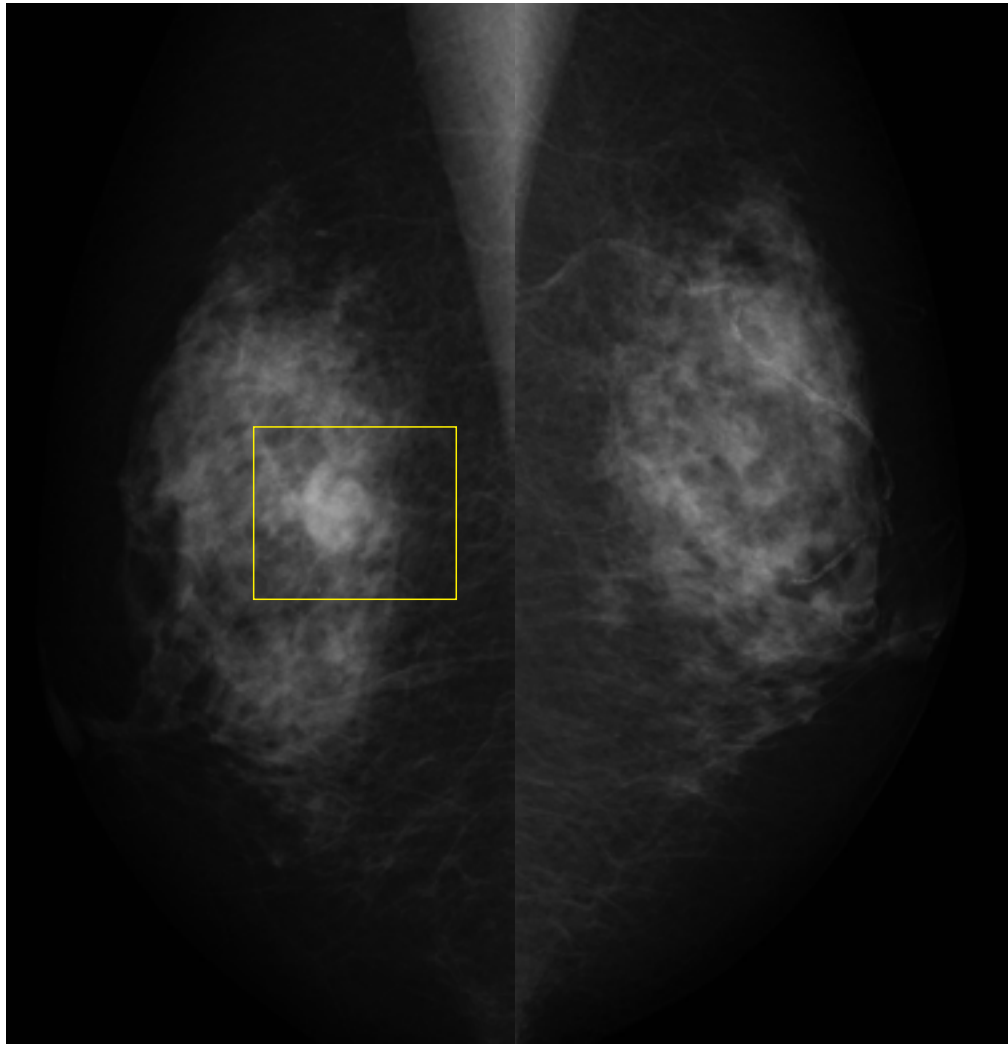
症例 17 (40歳代)



症例 18 (80歳代)



症例 19 (70歳代)



症例 20 (40歳代)

