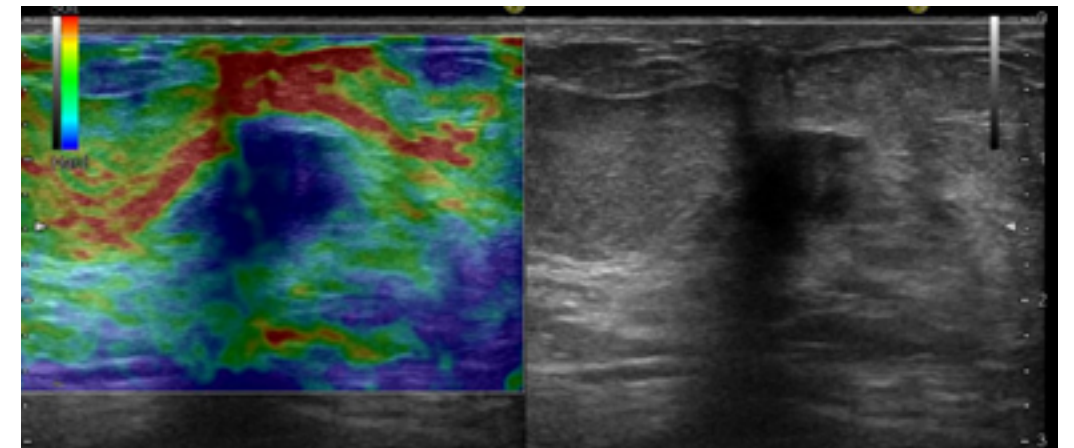
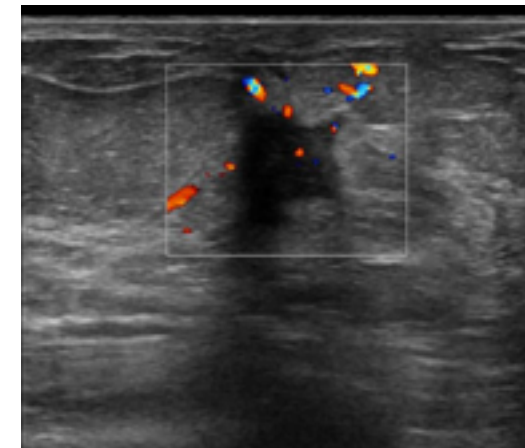
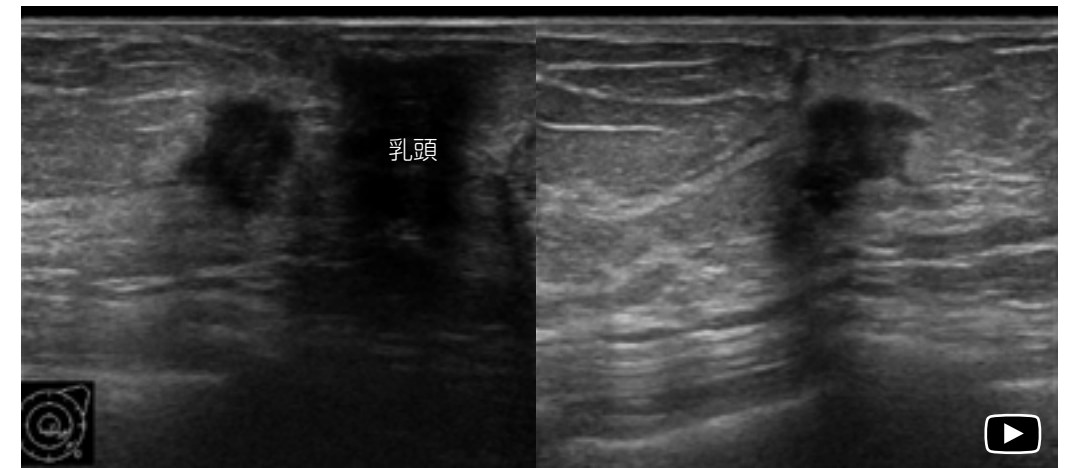
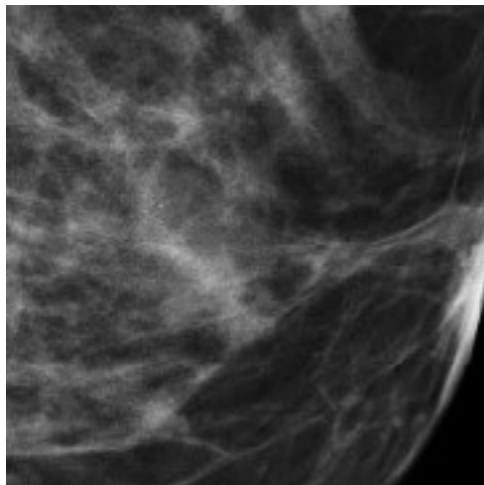
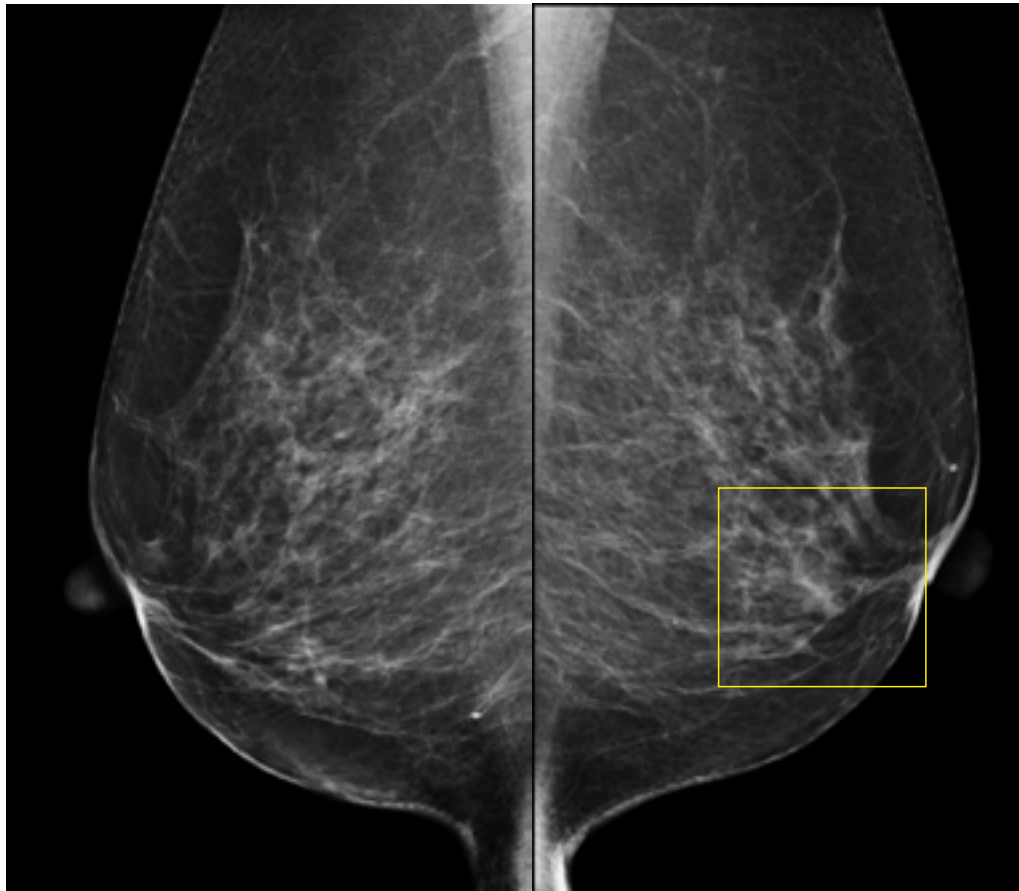
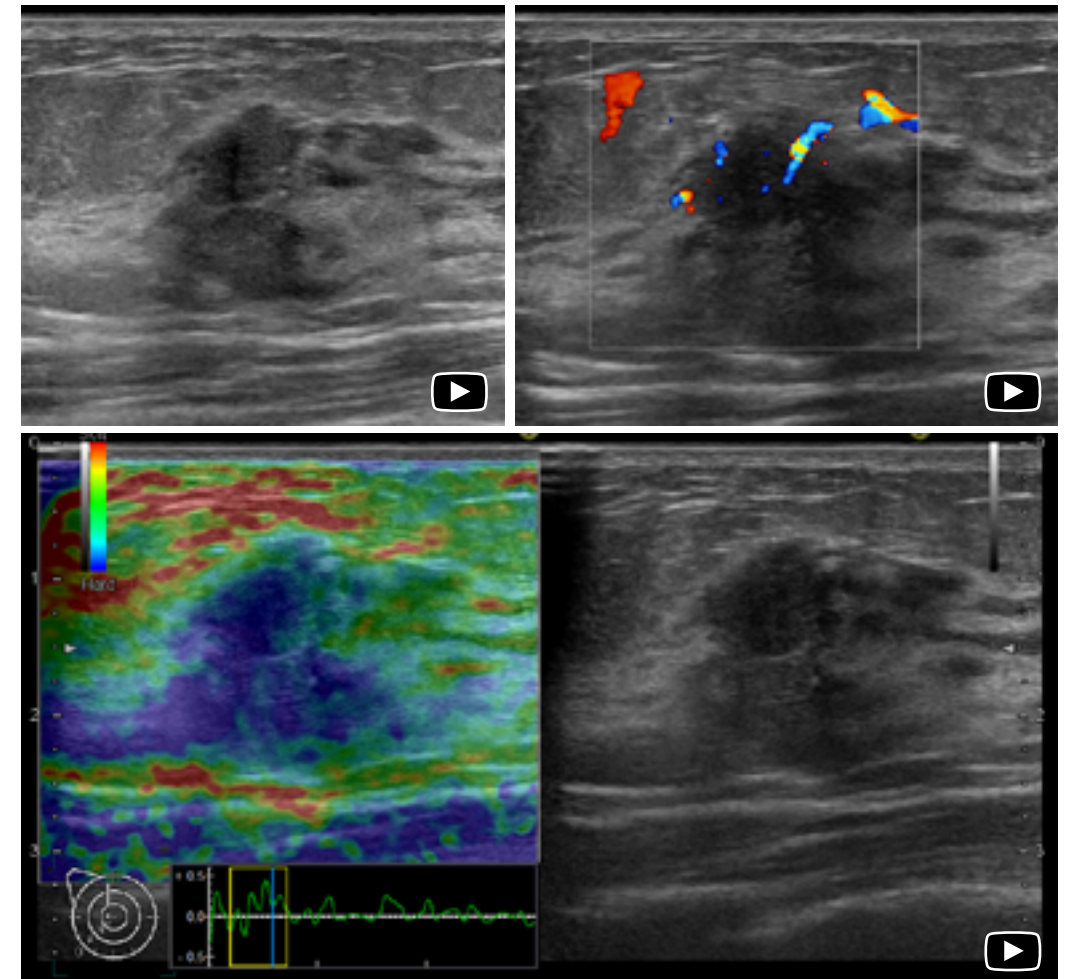
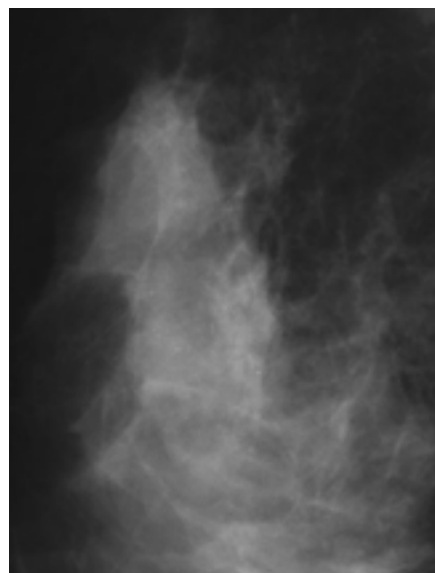
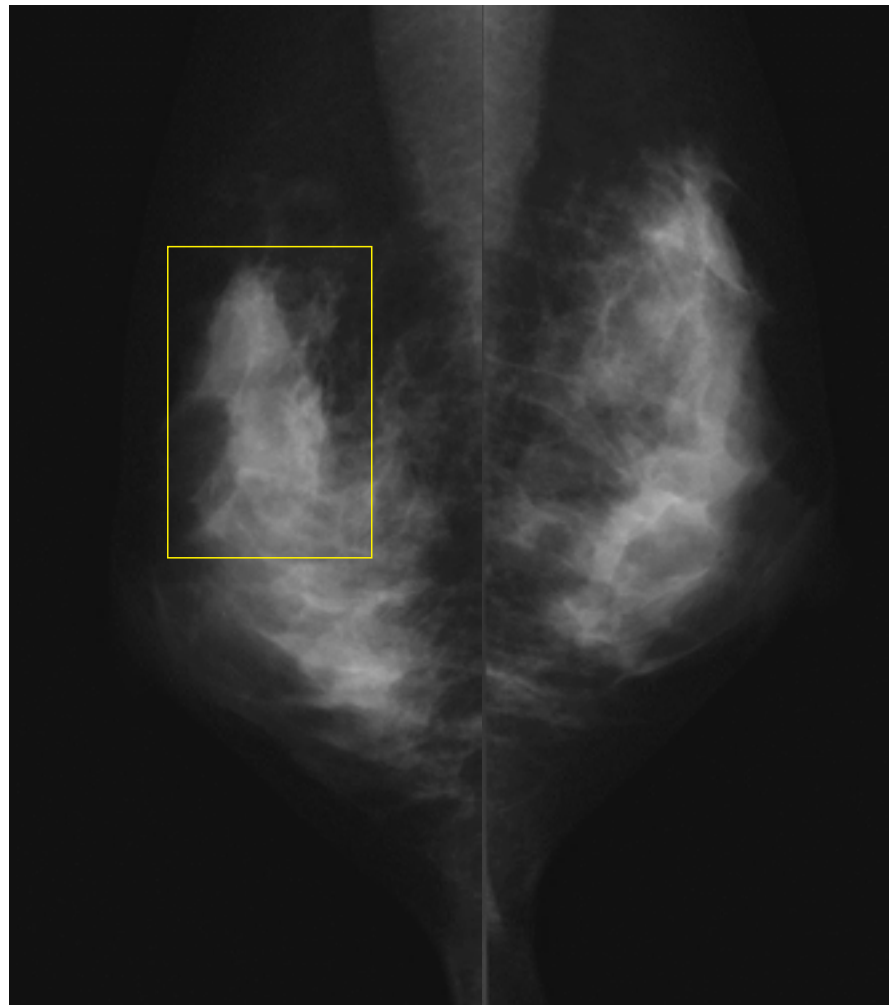


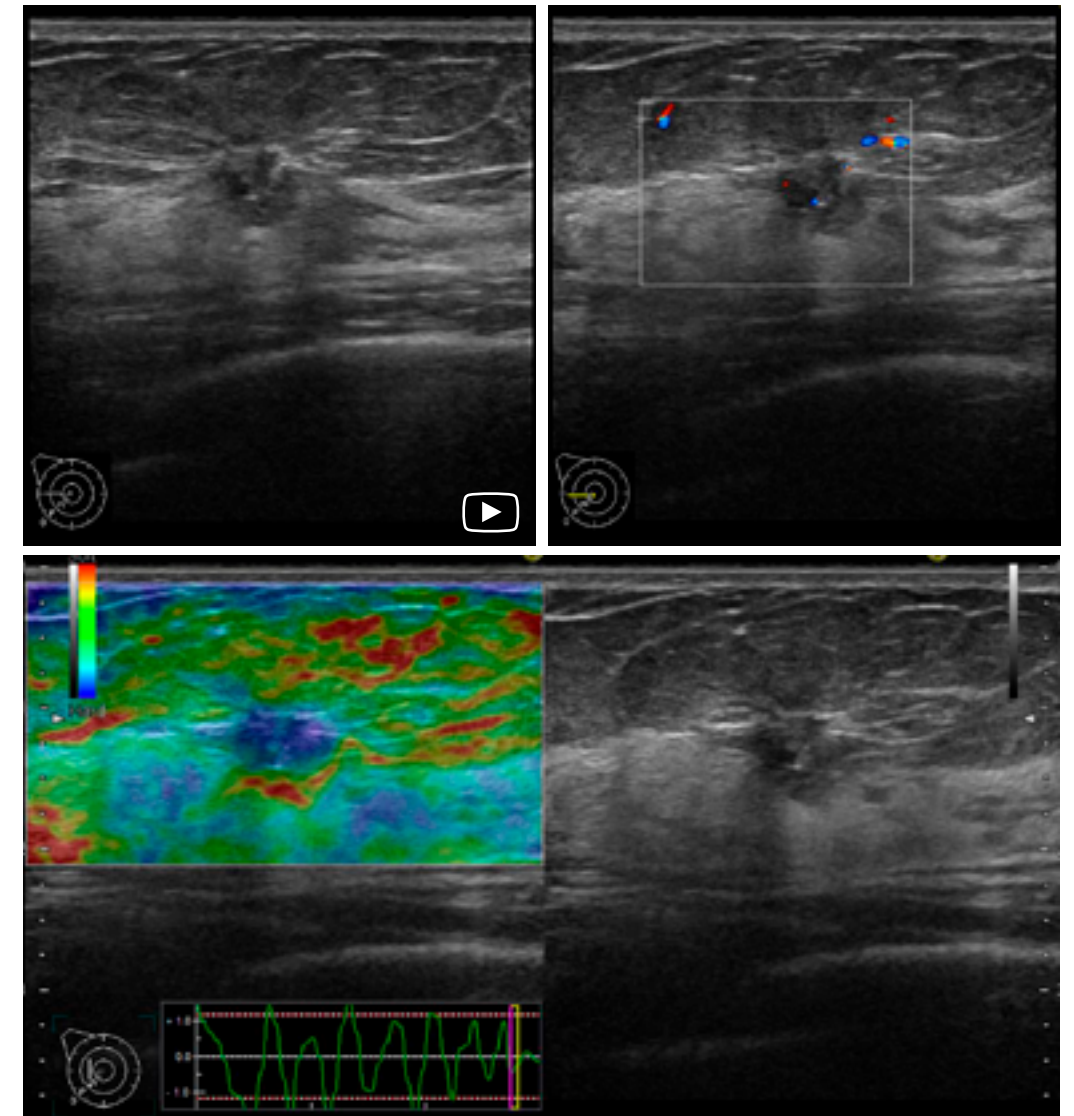
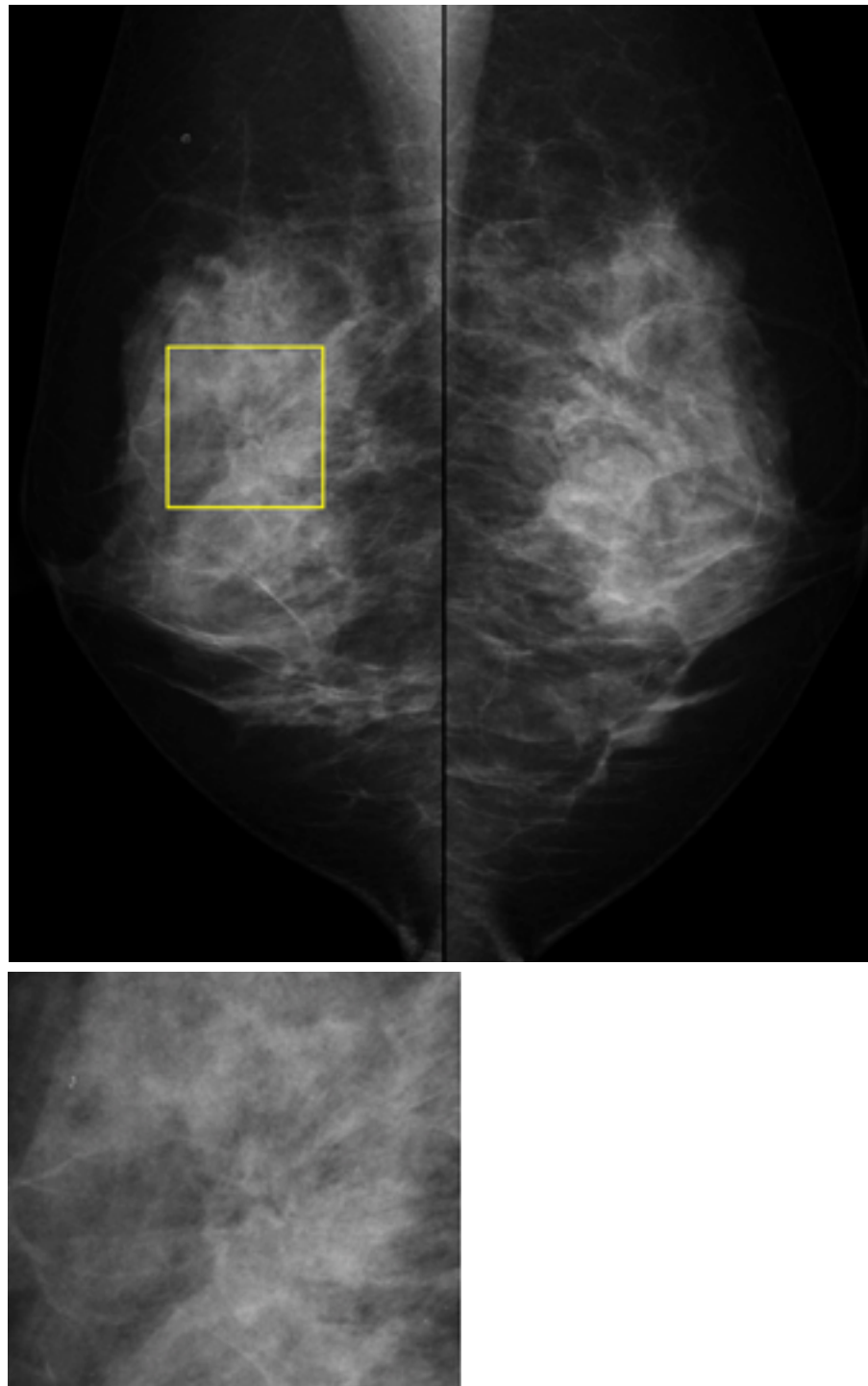
症例 21 (60歳代)



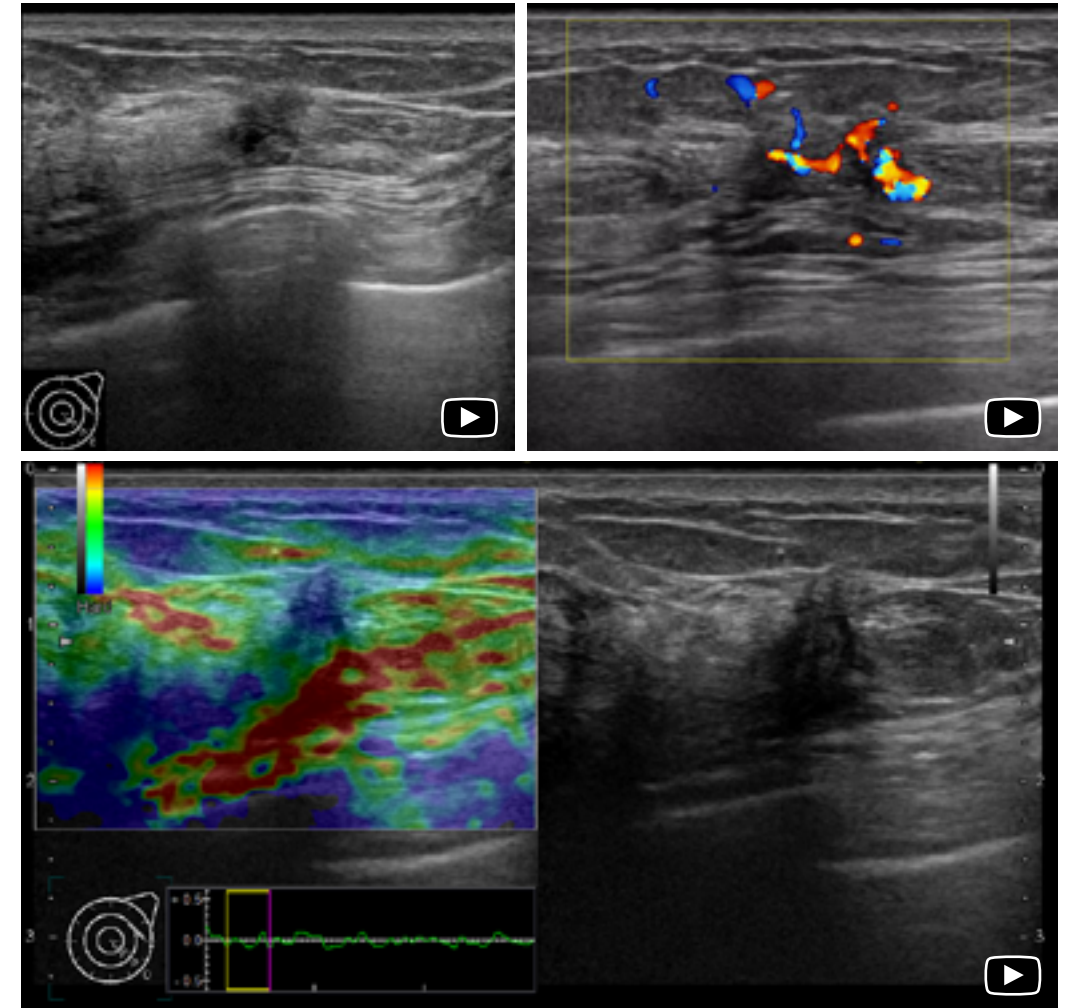
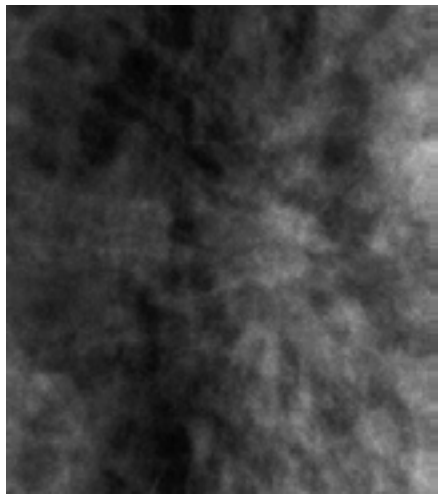
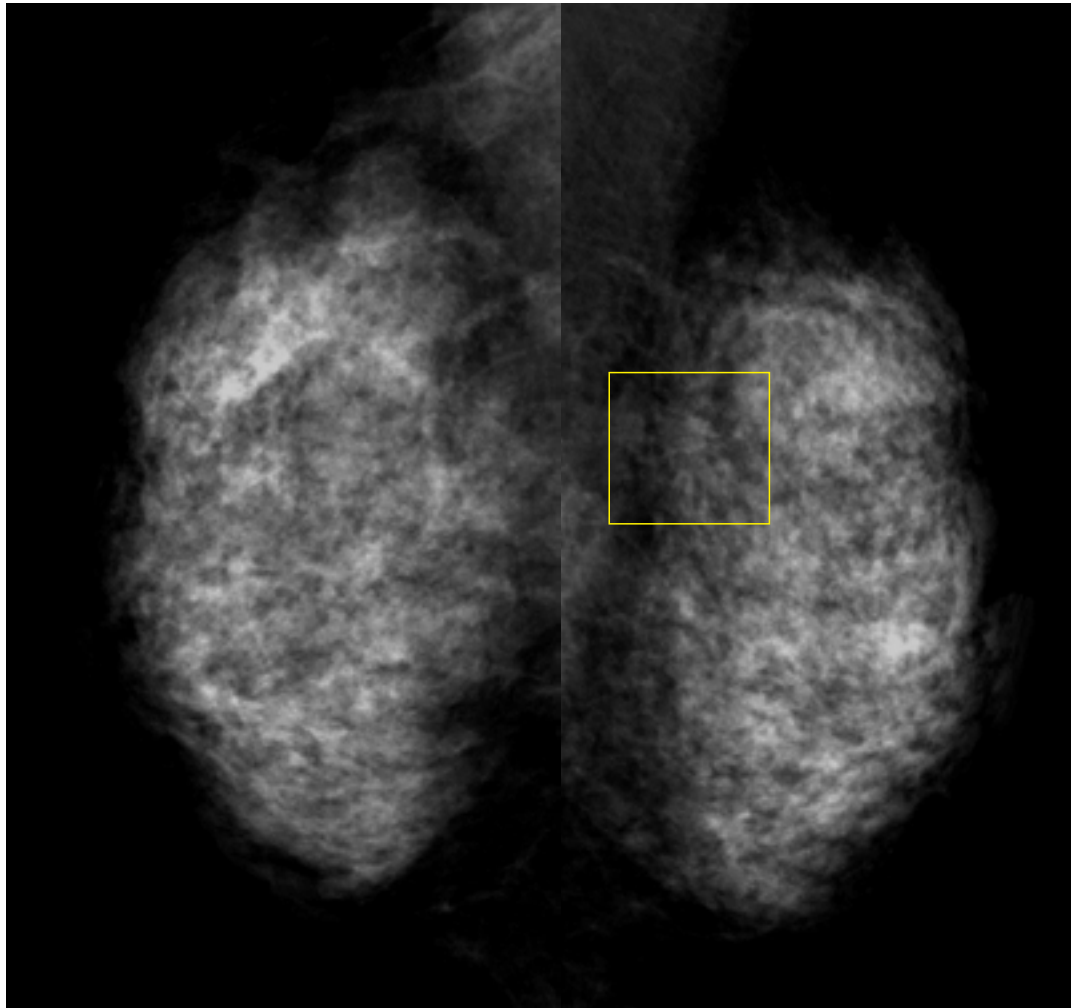
症例 22 (50歳代)



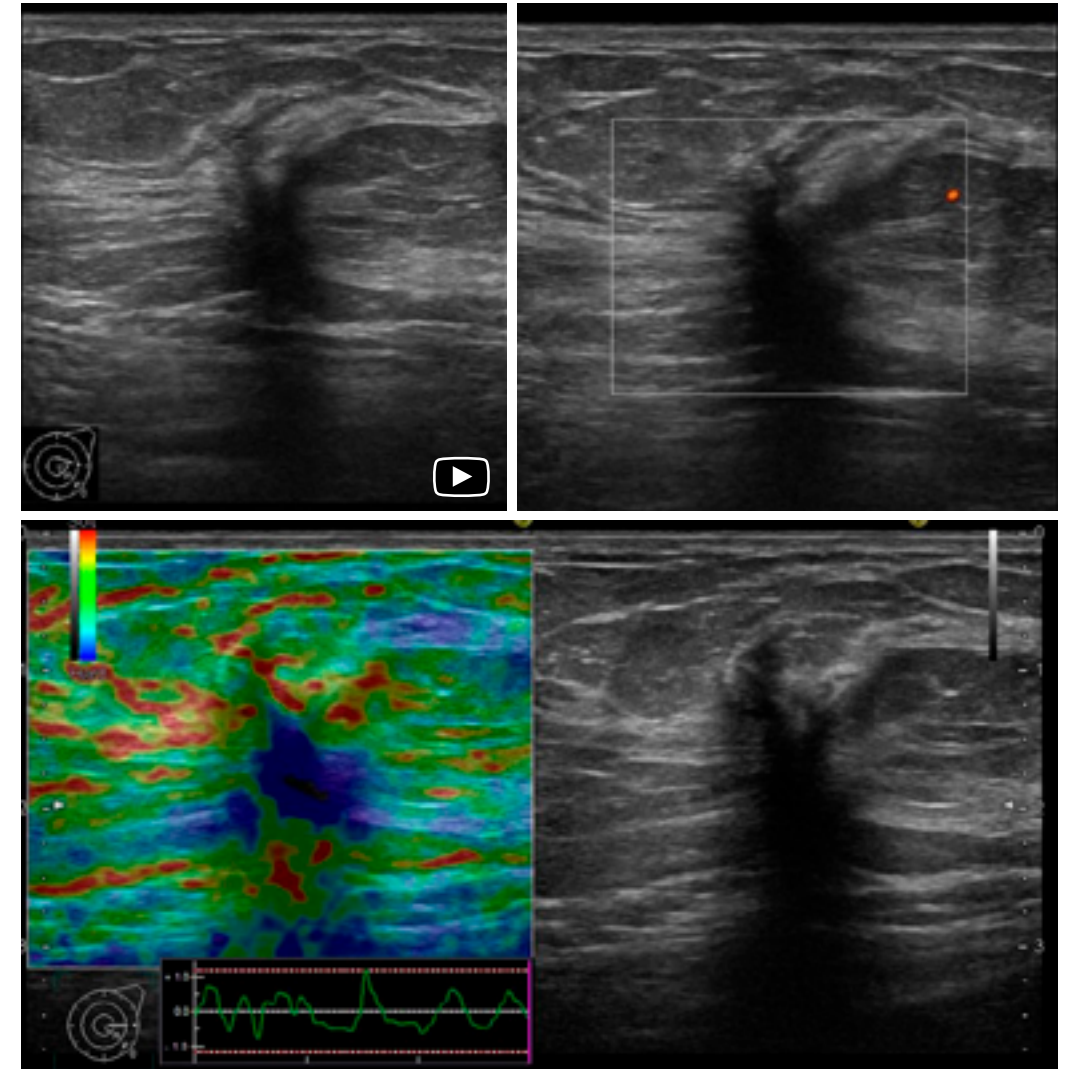
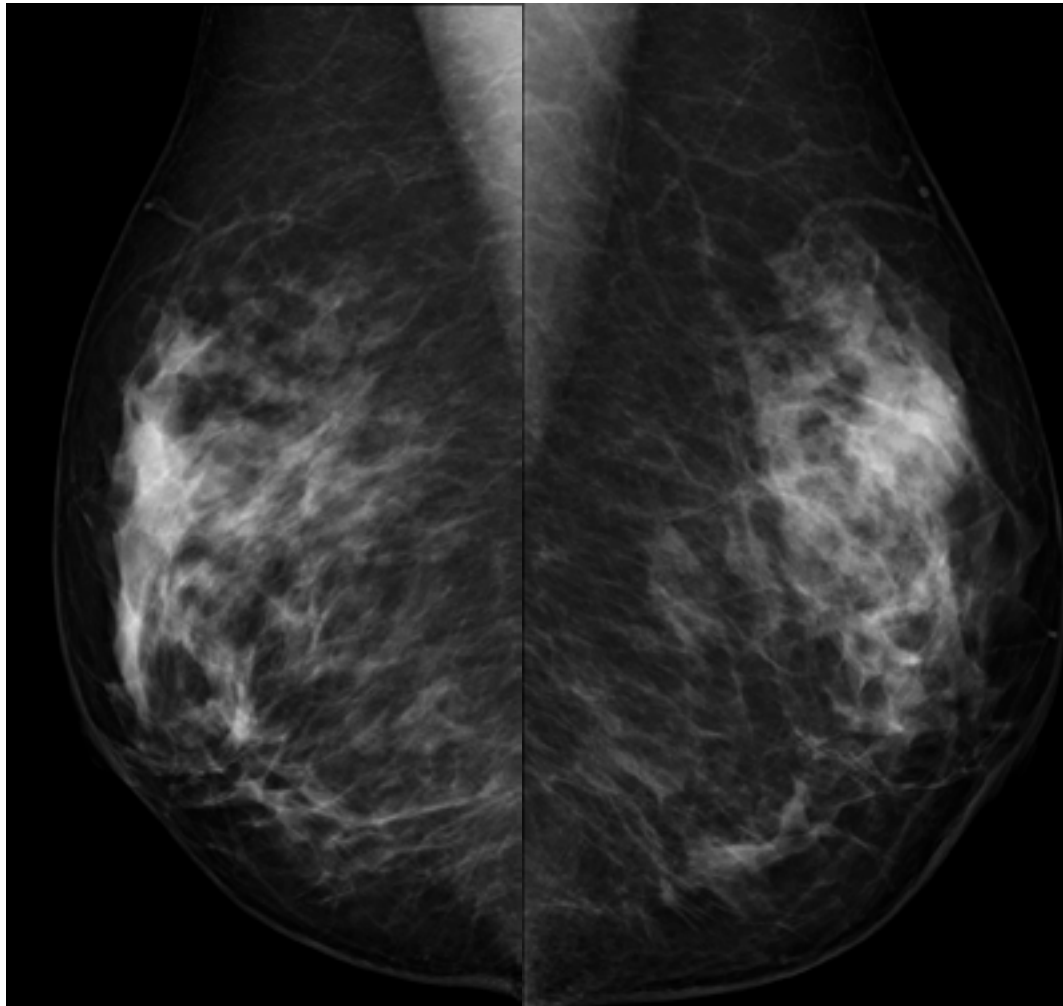
症例 23 (40歳代)



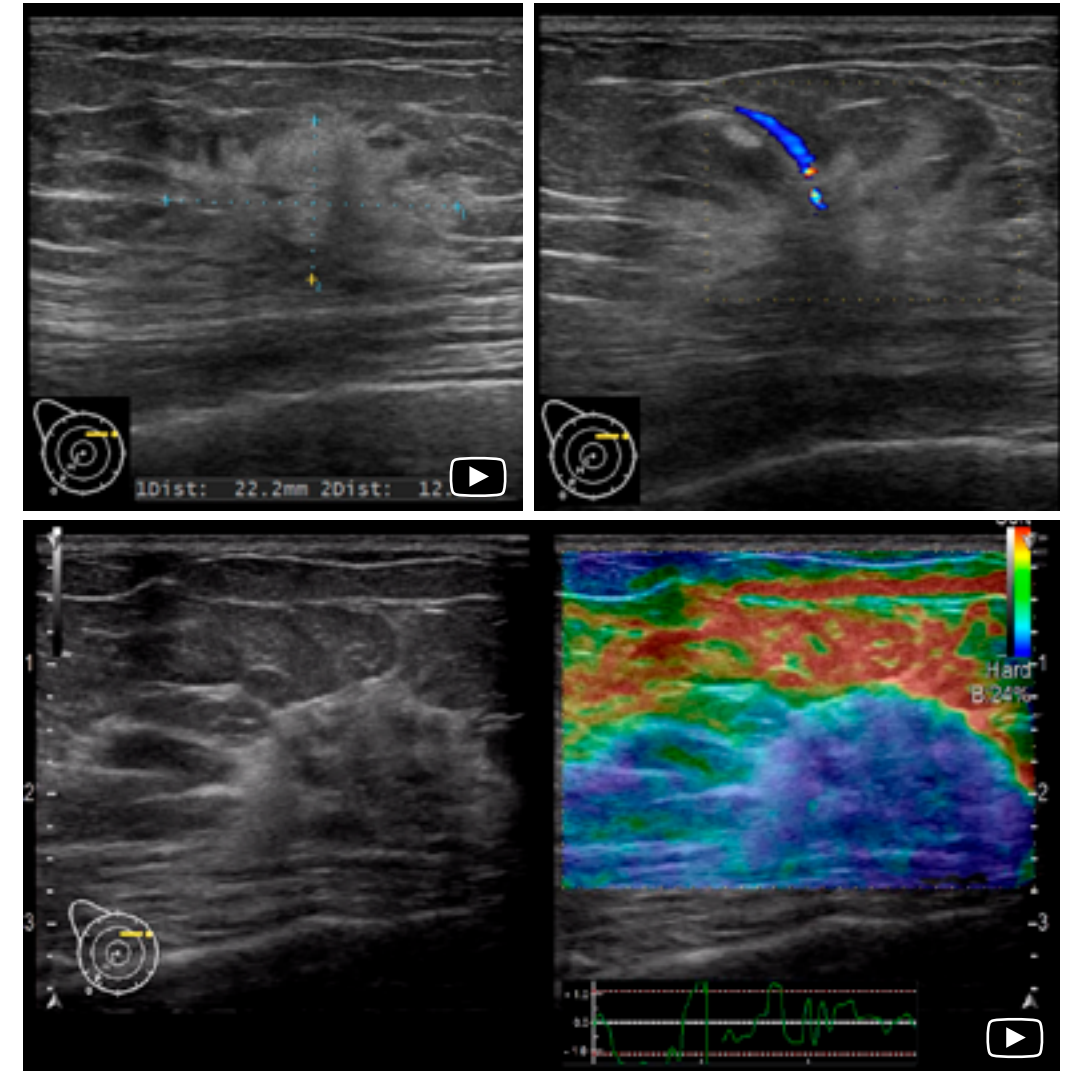
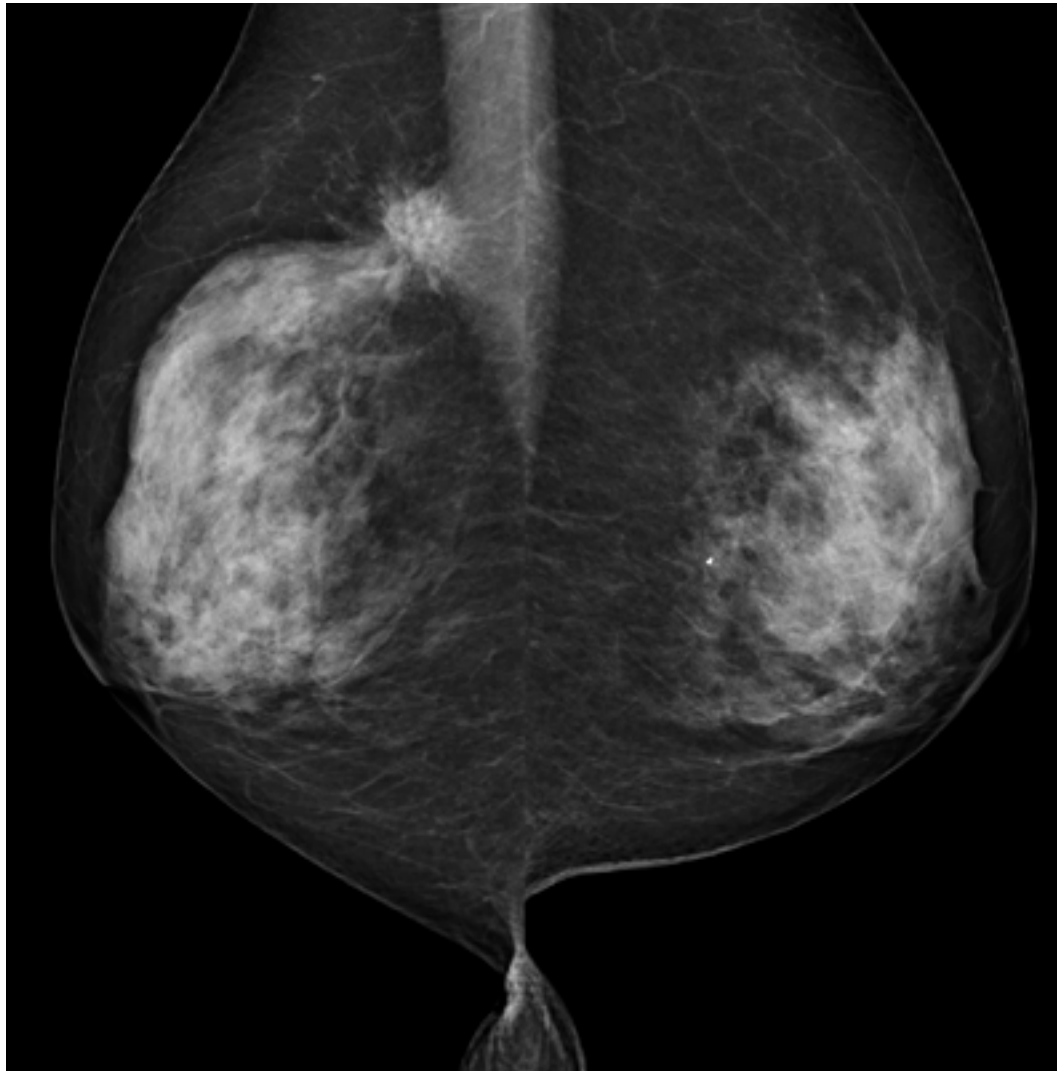
症例 24 (50歳代)



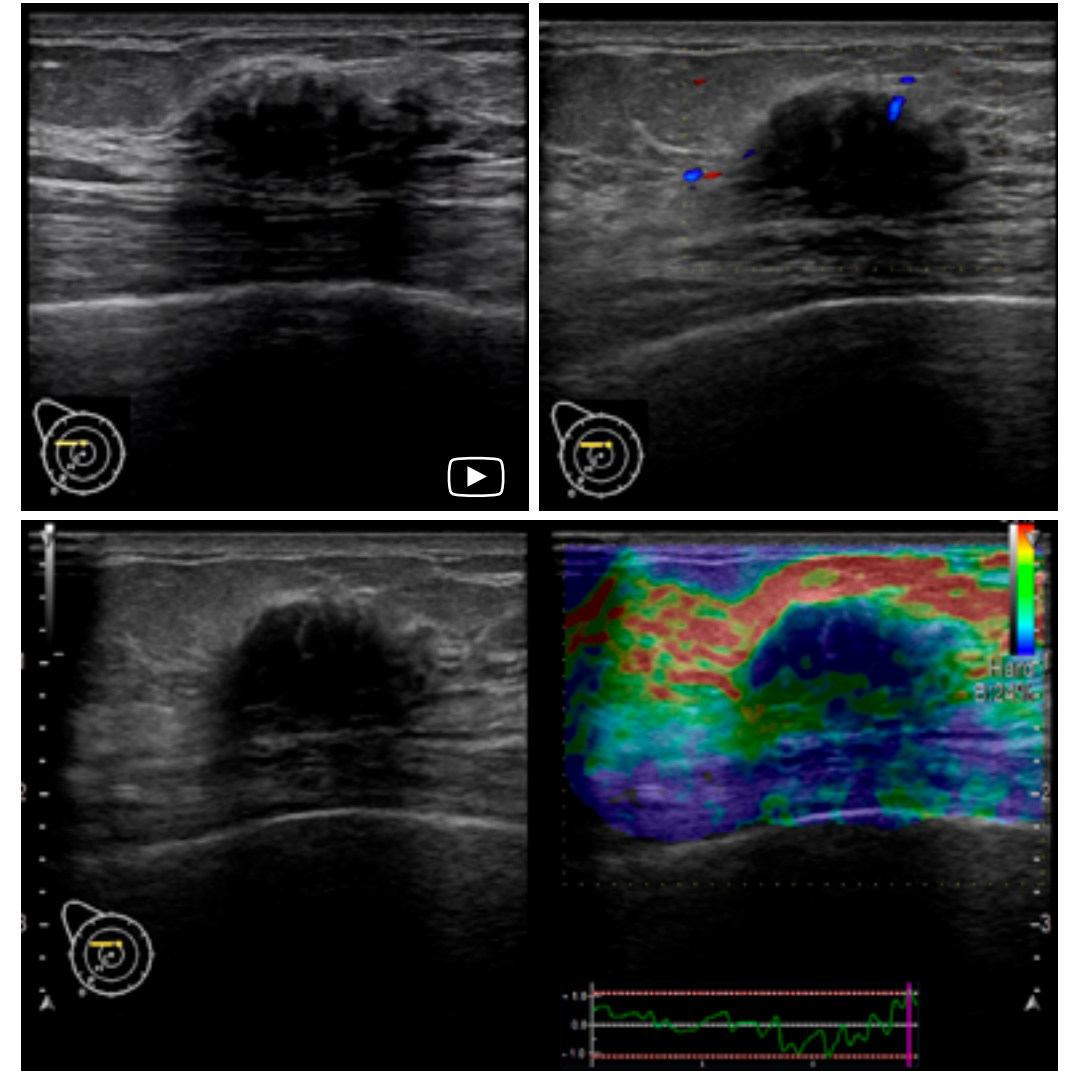
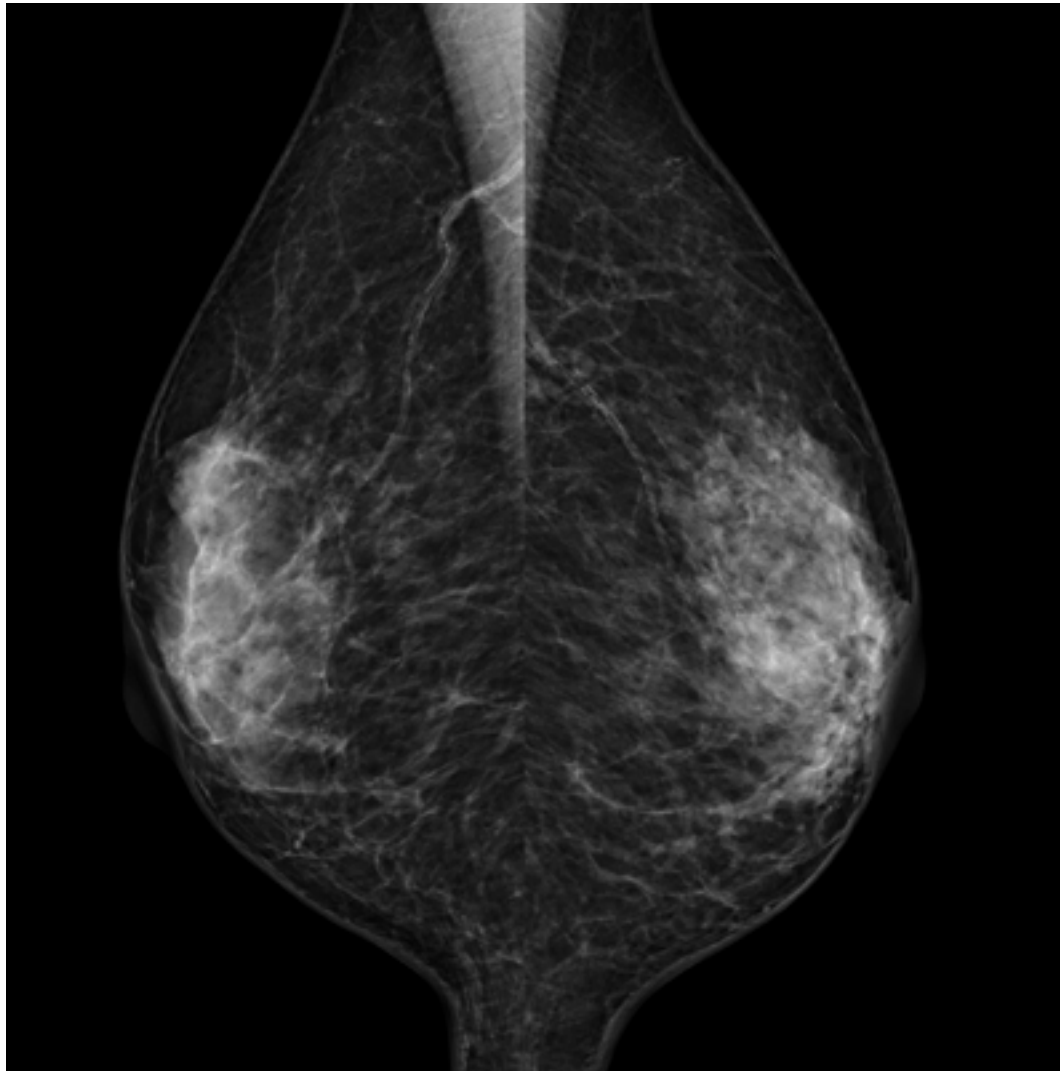
症例 25 (50歳代)



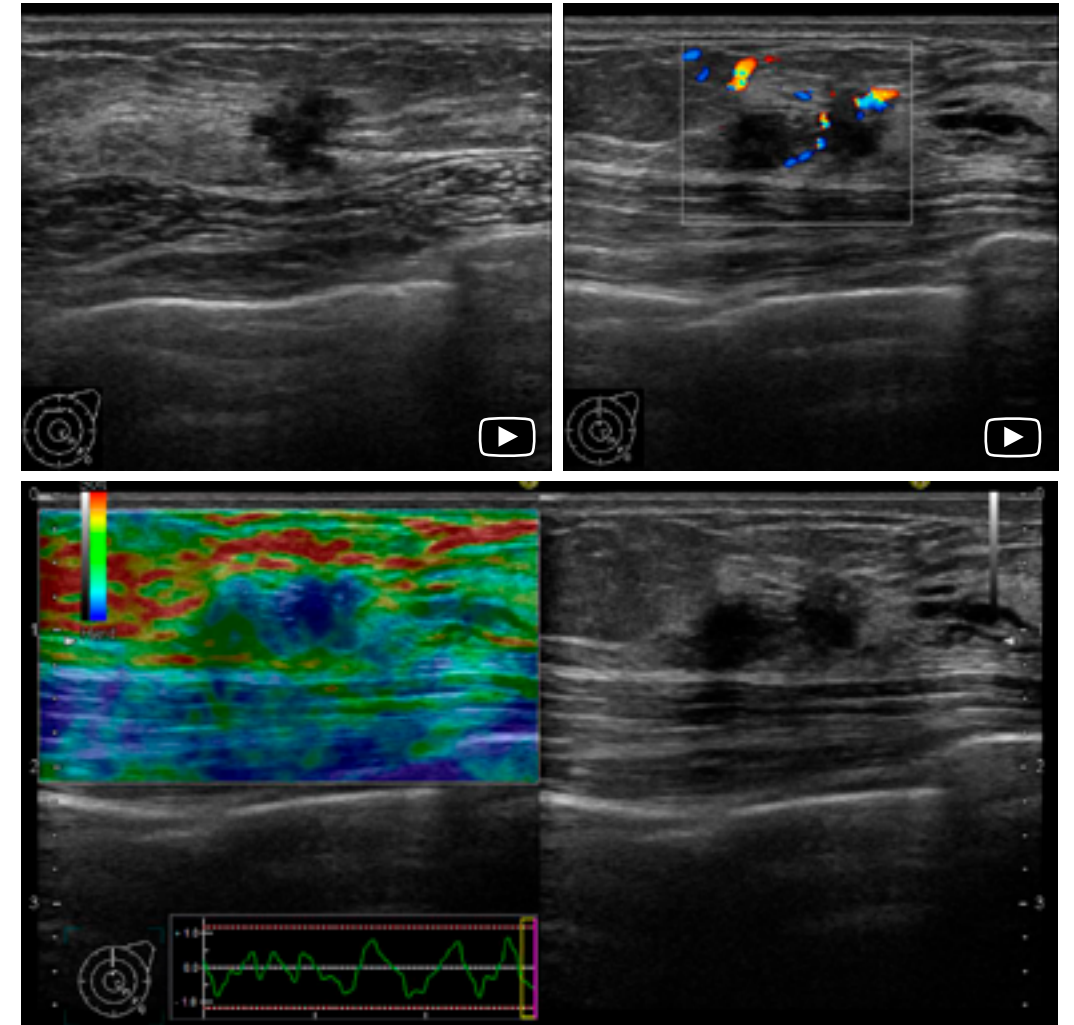
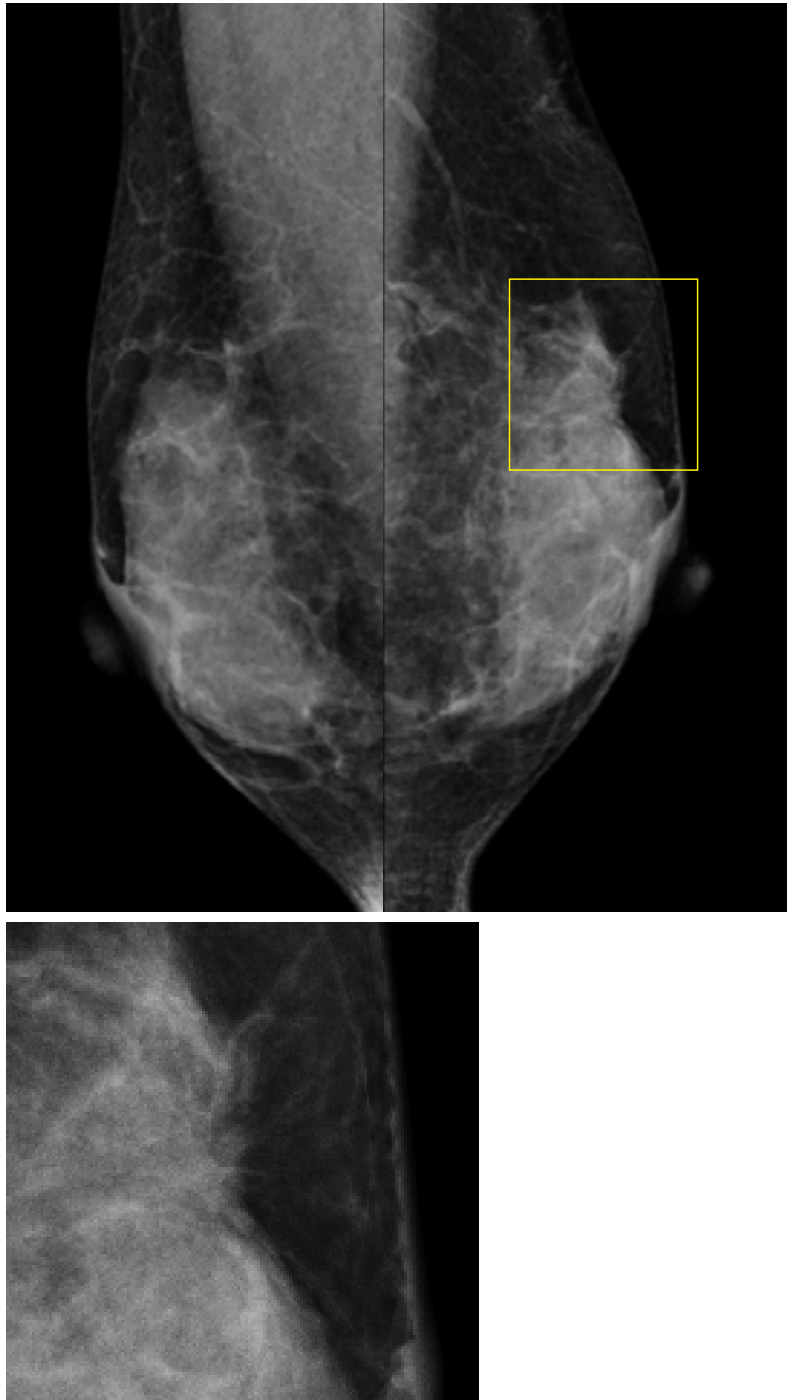
症例 26 (70歳代)



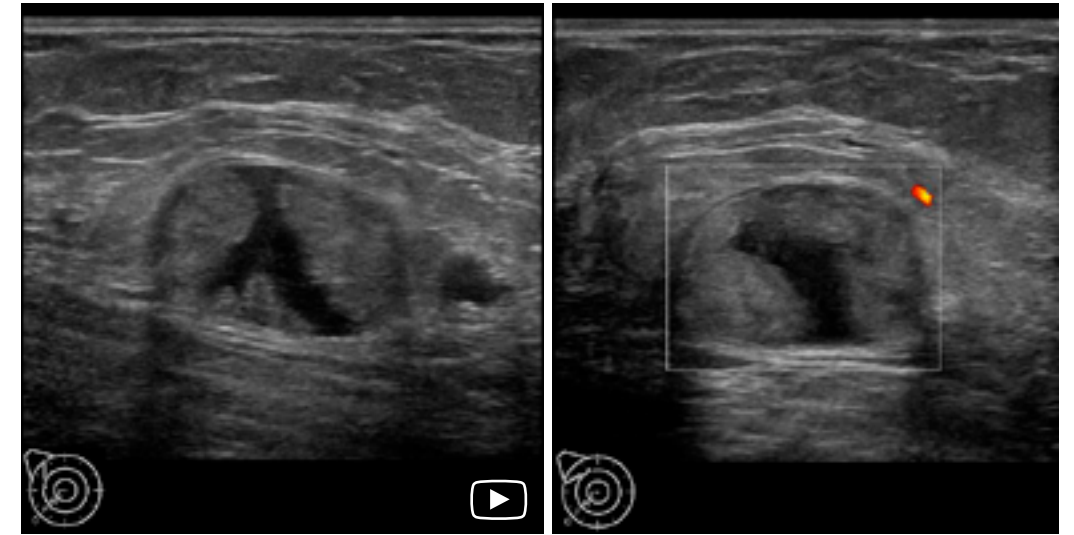
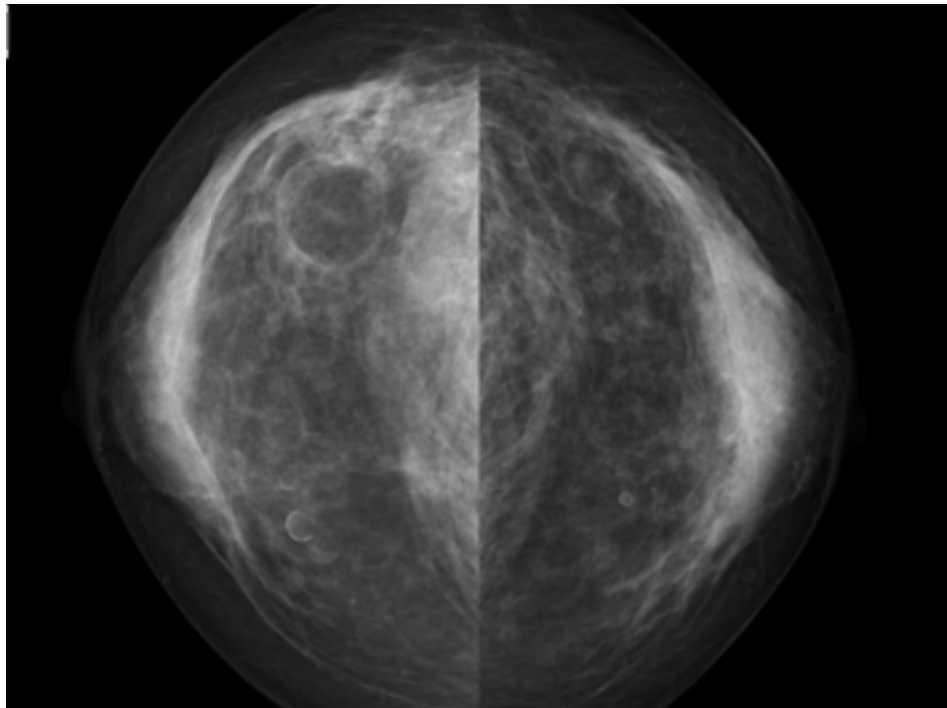
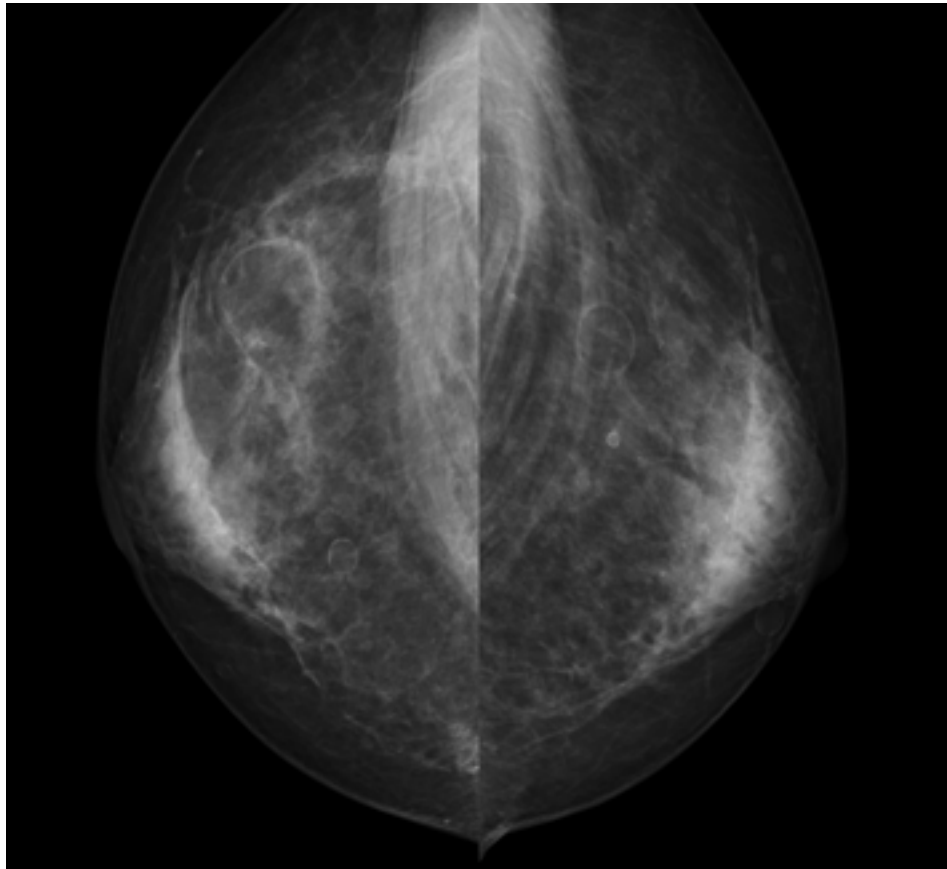
症例 27 (70歳代)



症例 28 (40歳代)



症例 29 (40歳代)



症例 30 (90歳代)

