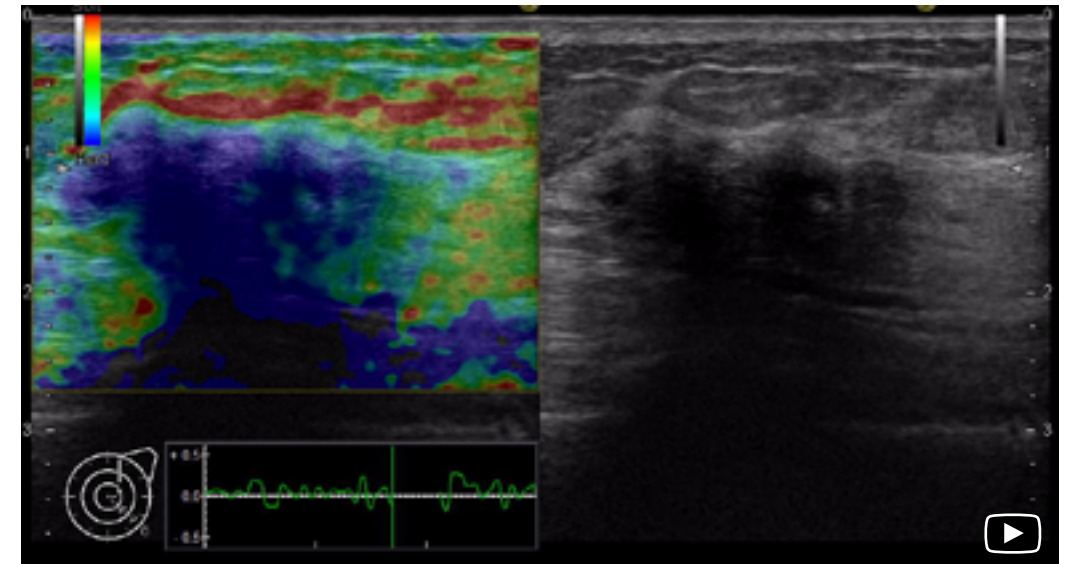
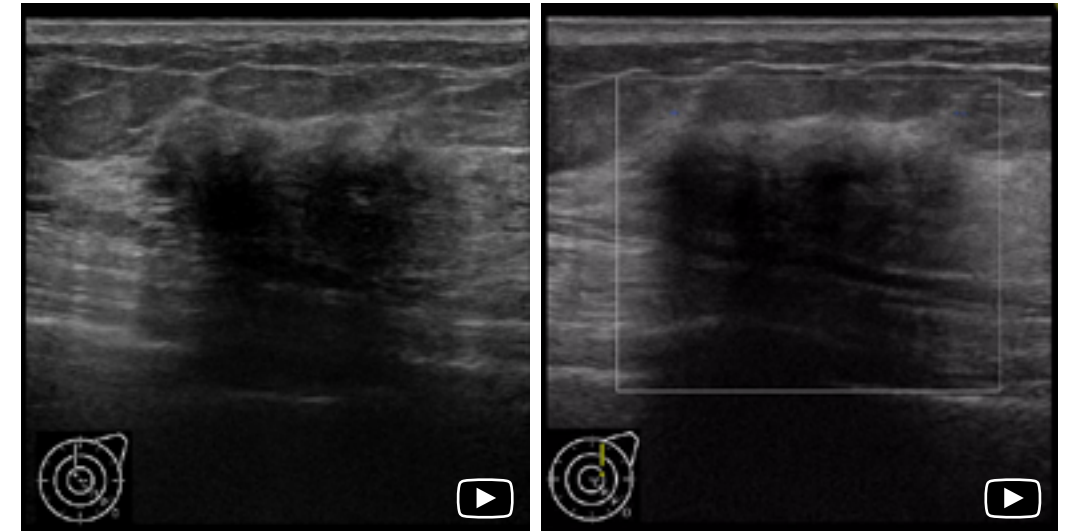
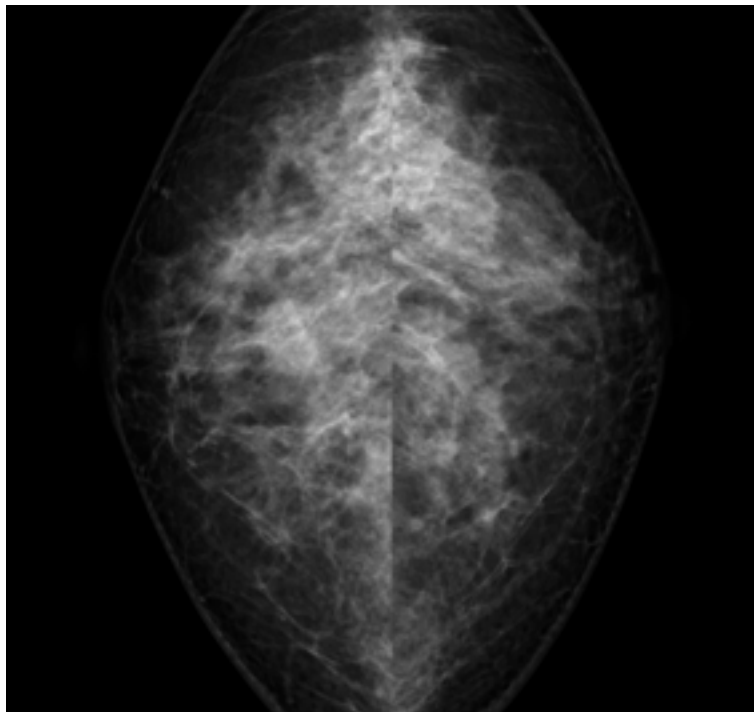
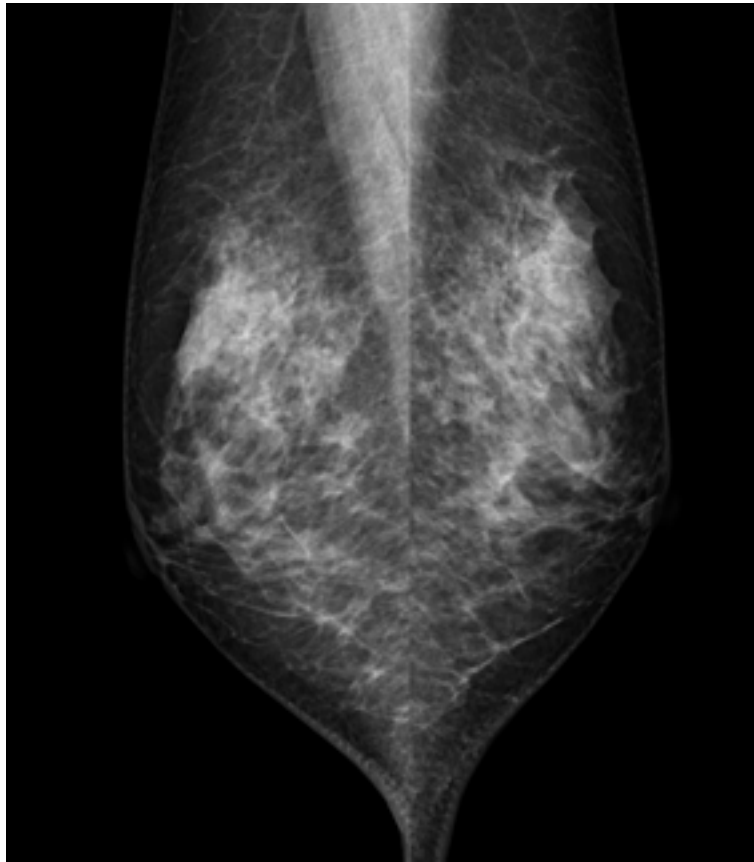
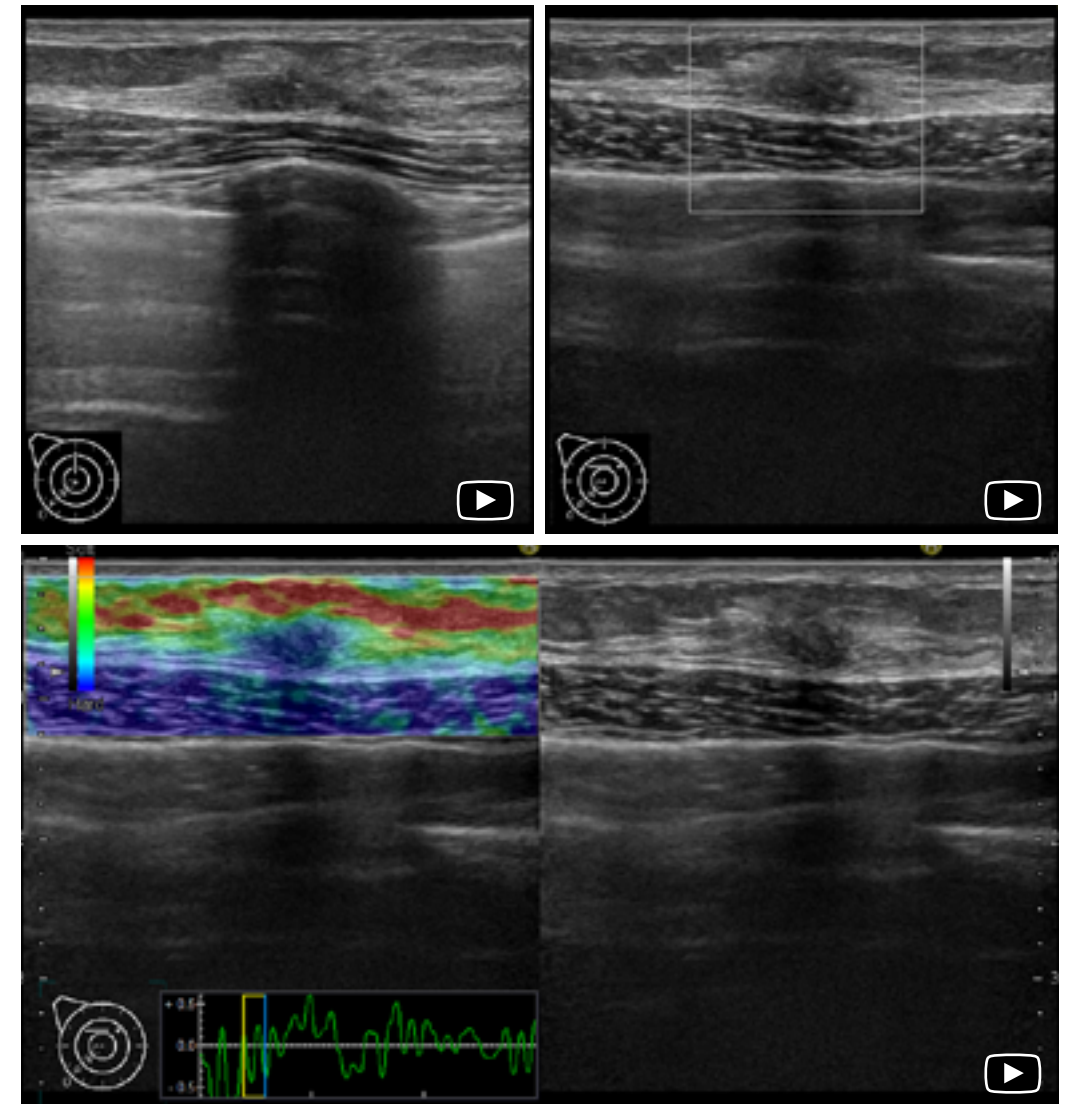
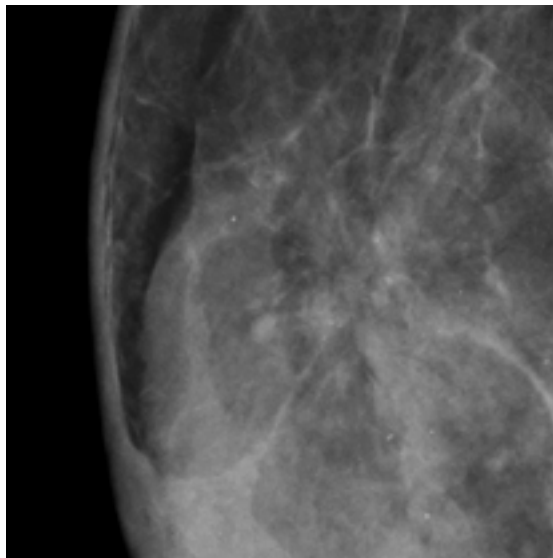
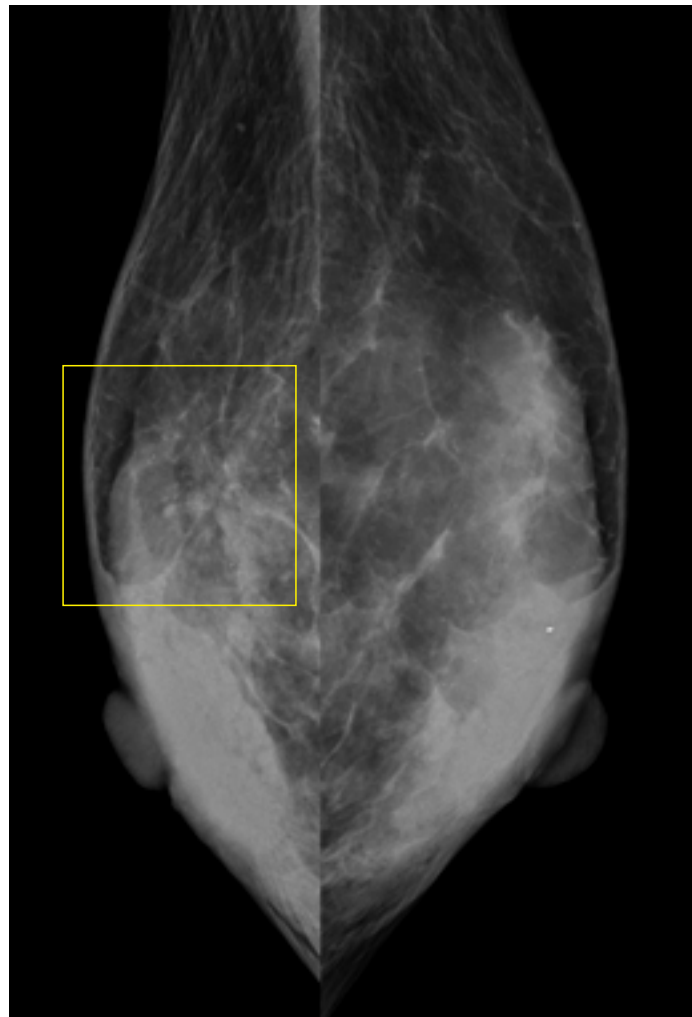


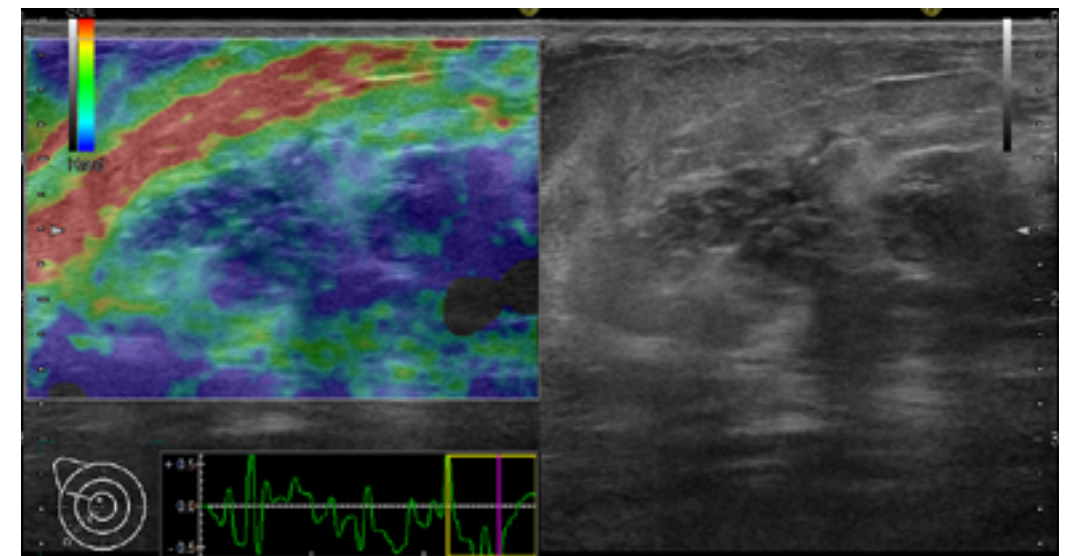
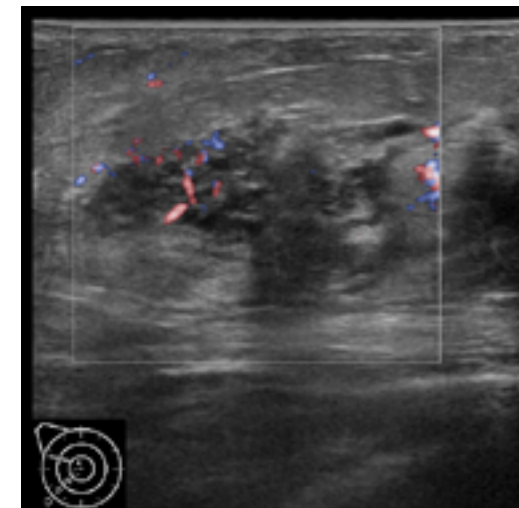
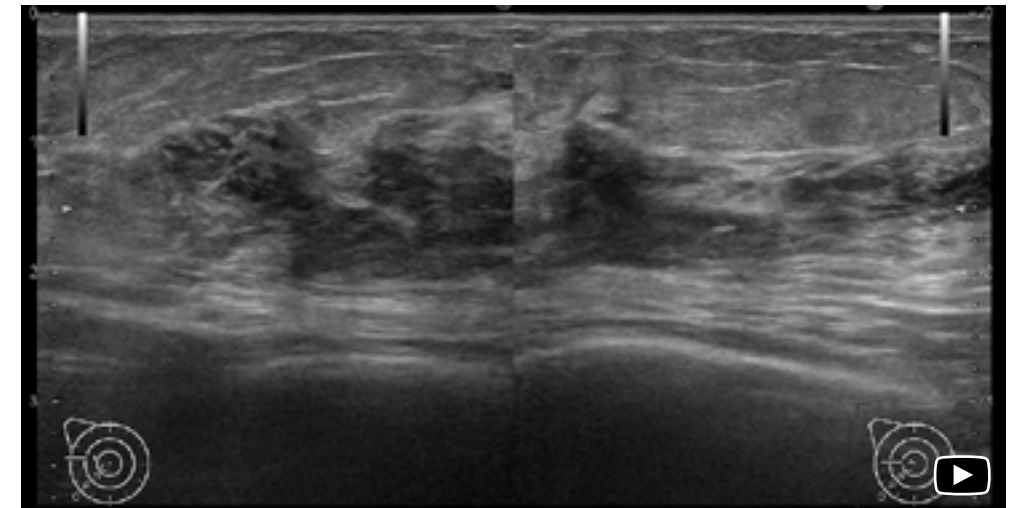
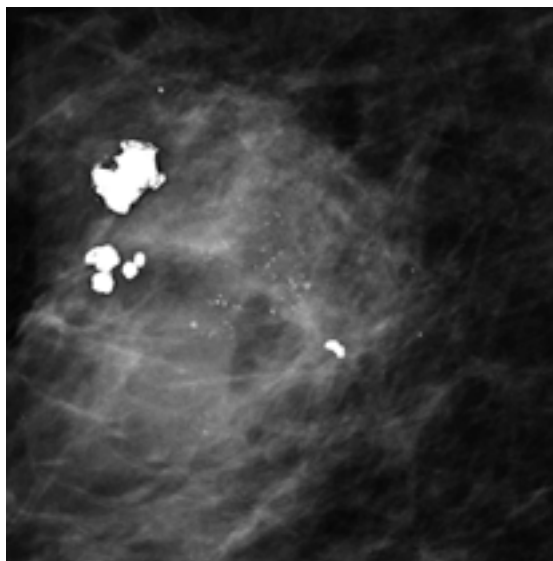
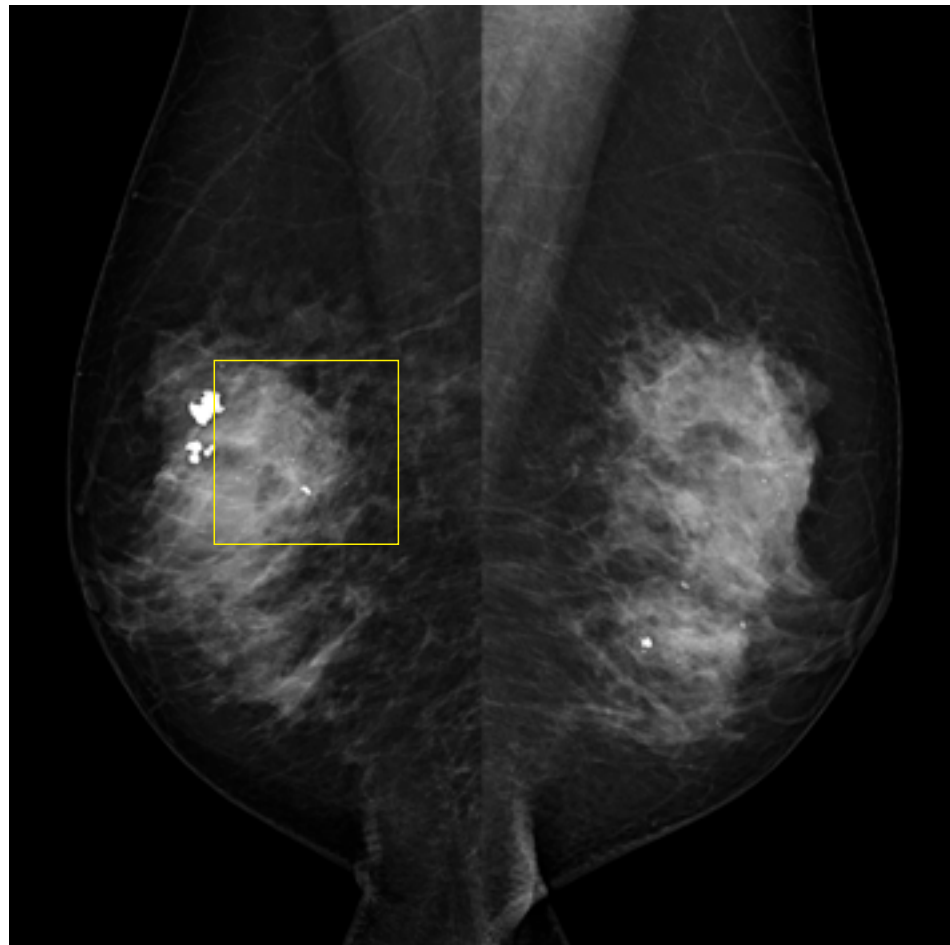
症例 11 (60歳代)



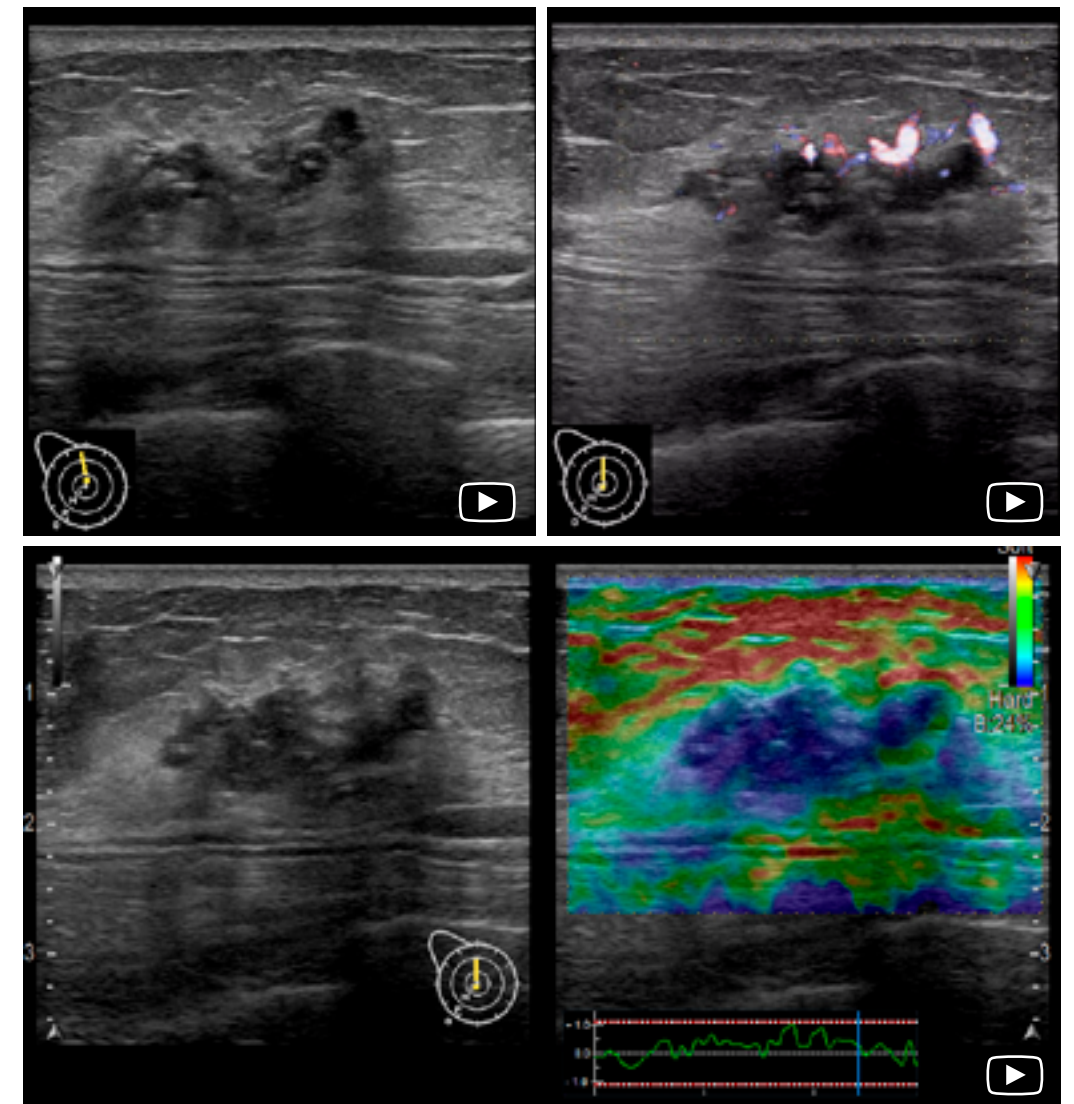
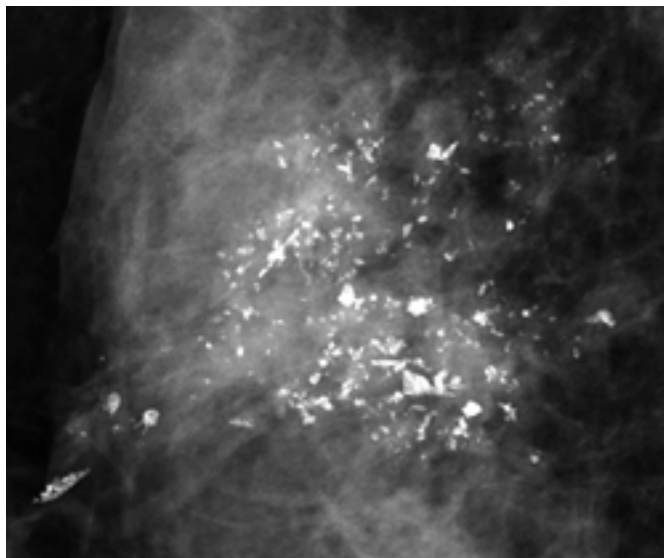
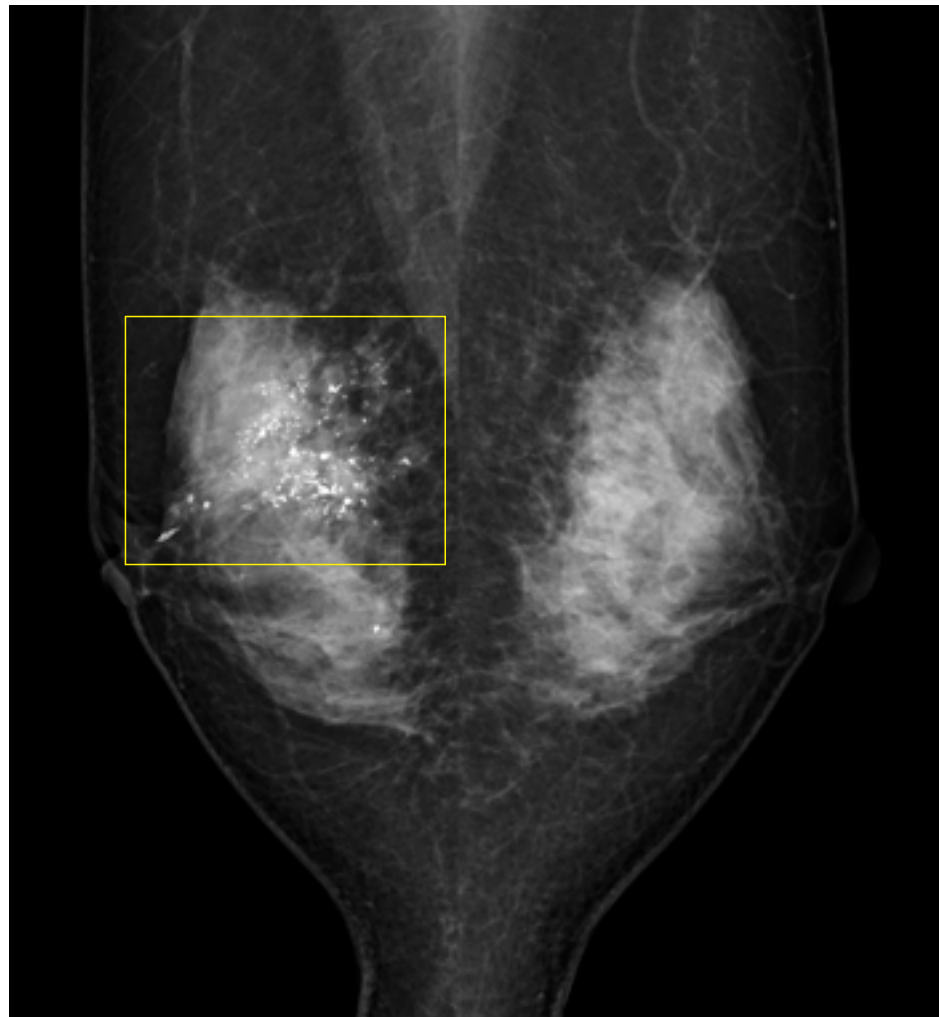
症例 12 (50歳代)



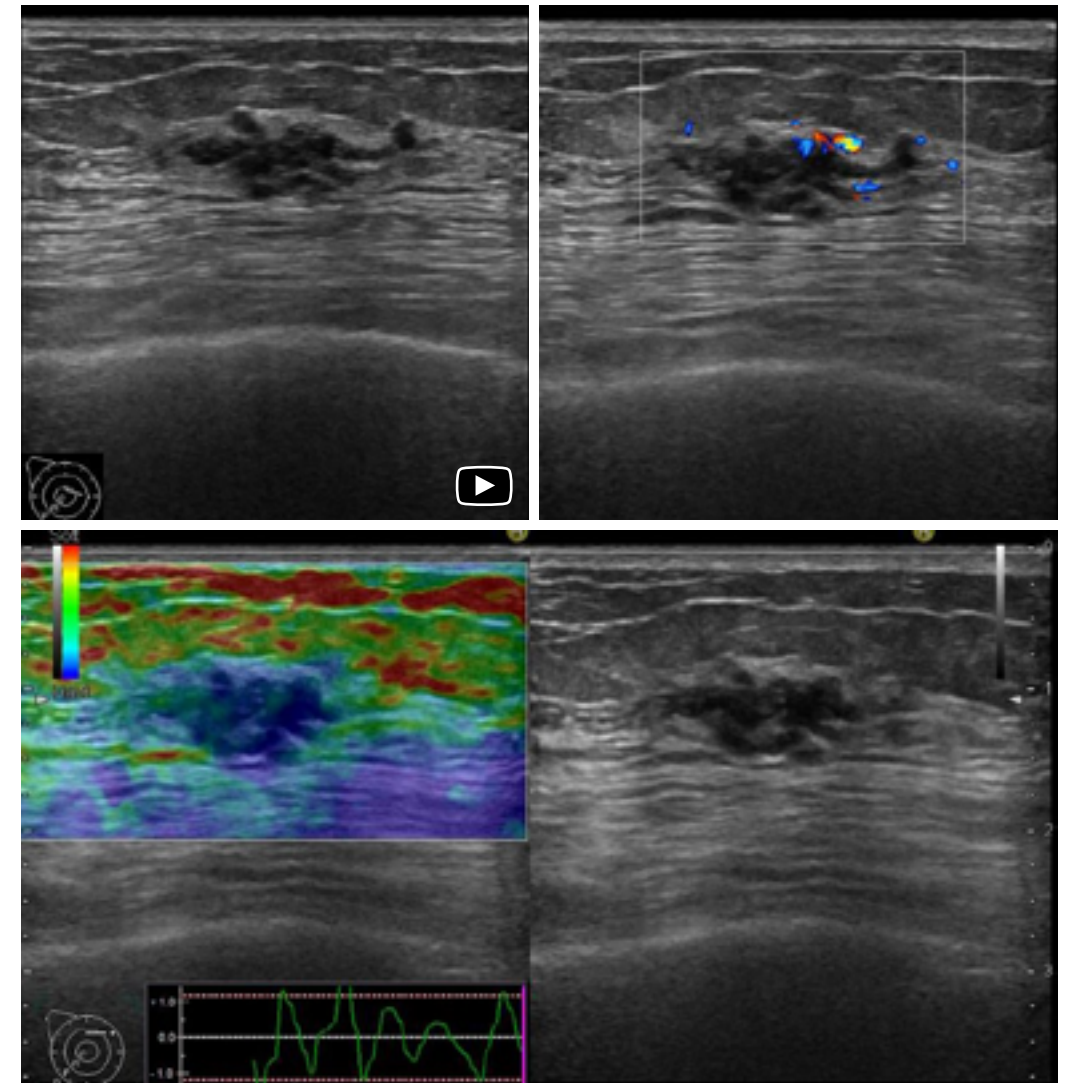
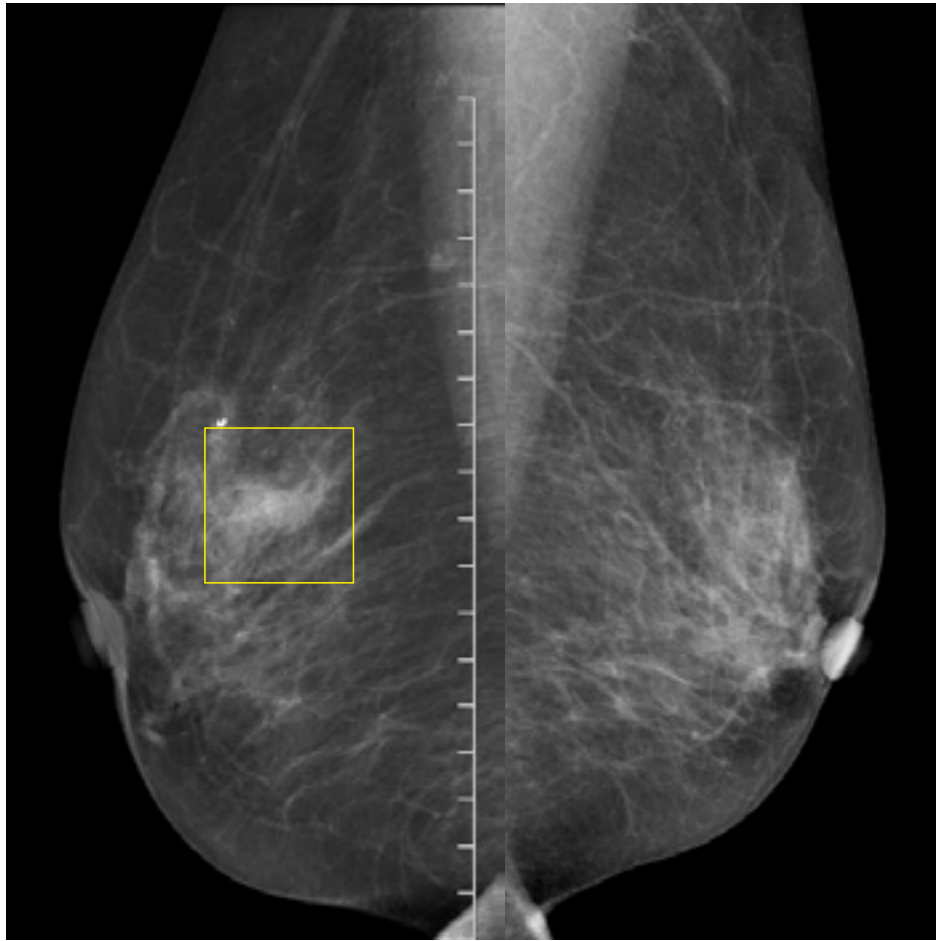
症例 13 (60歳代)



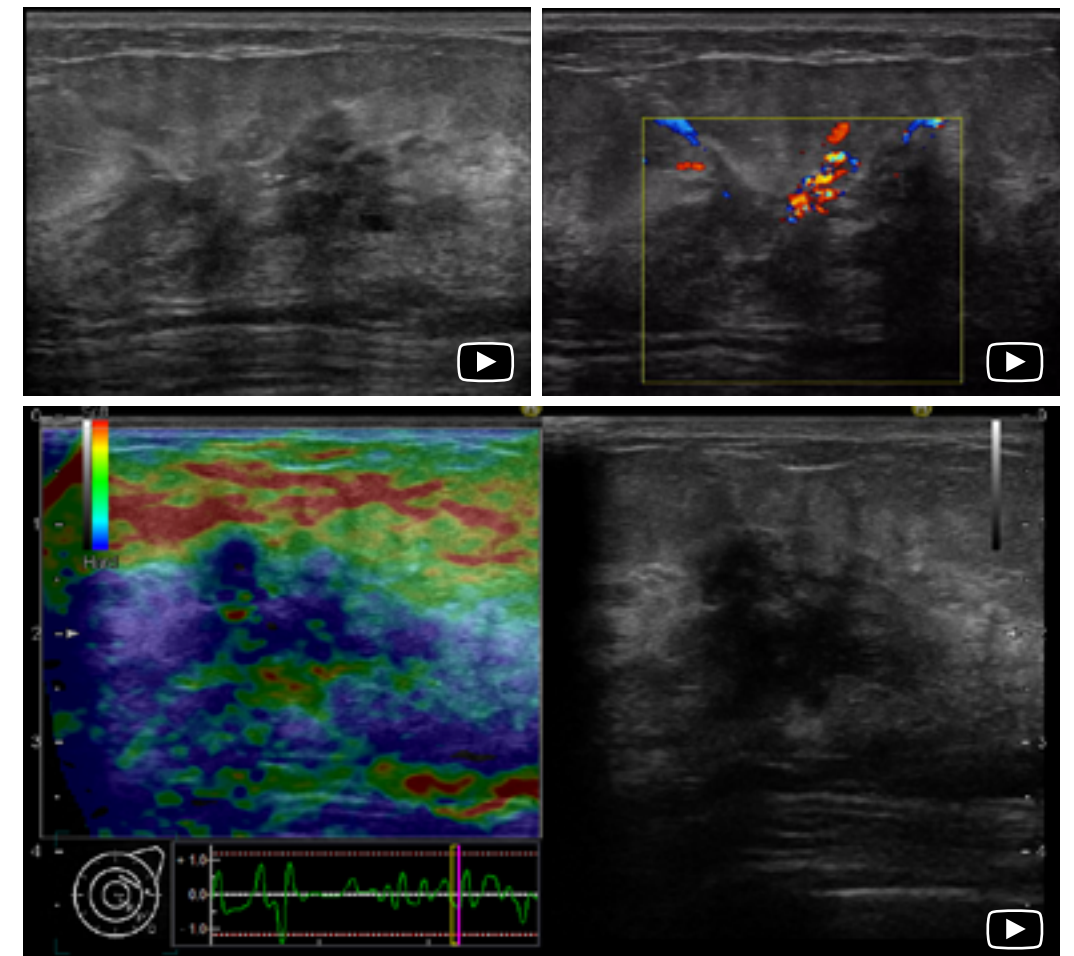
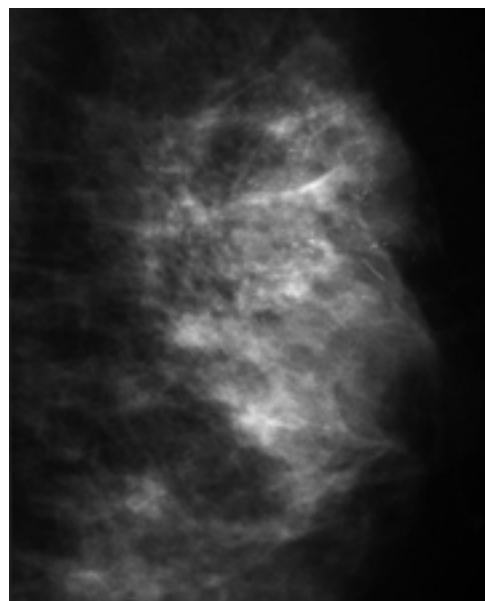
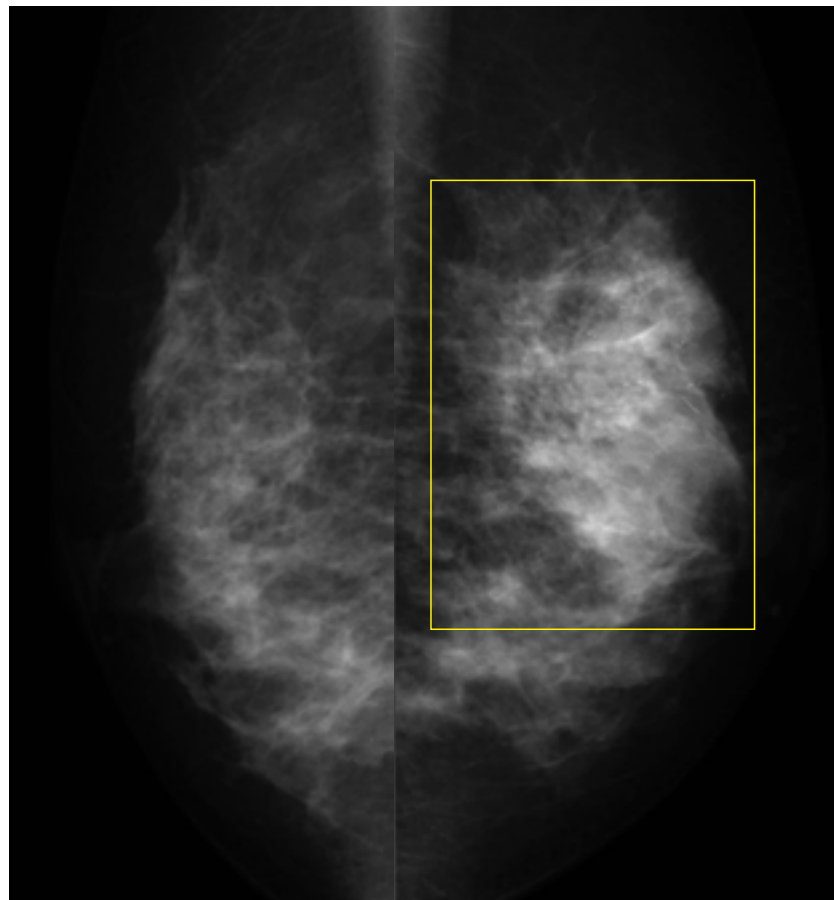
症例 14 (50歳代)



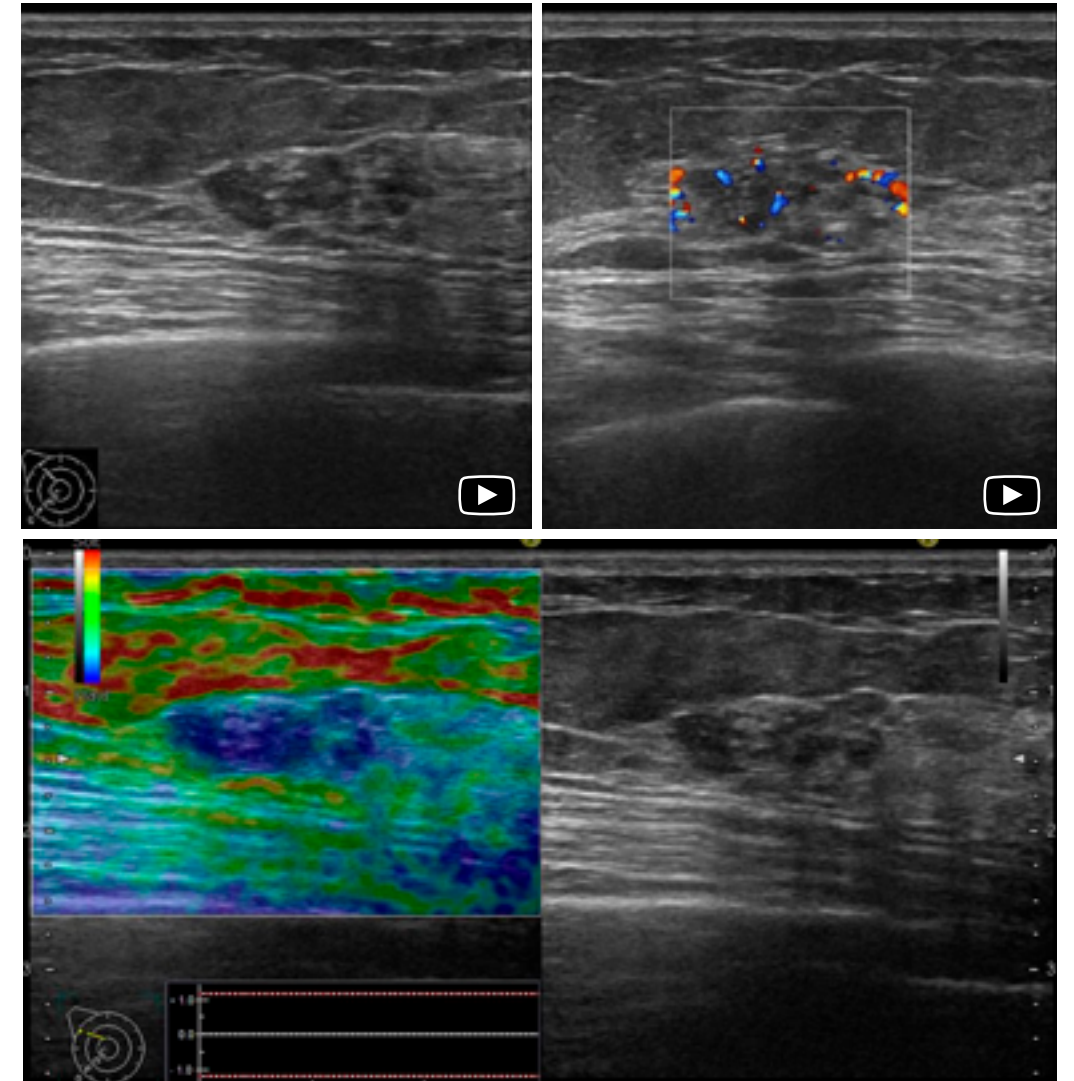
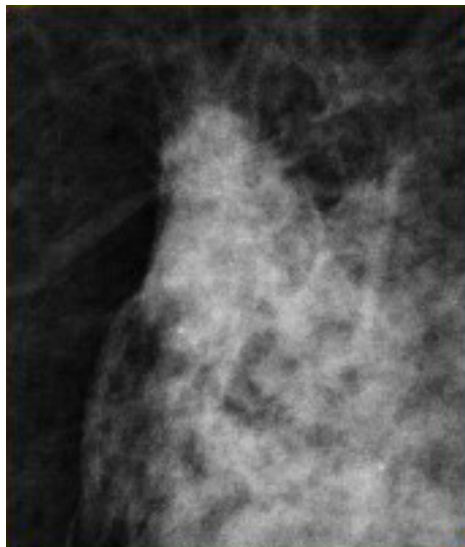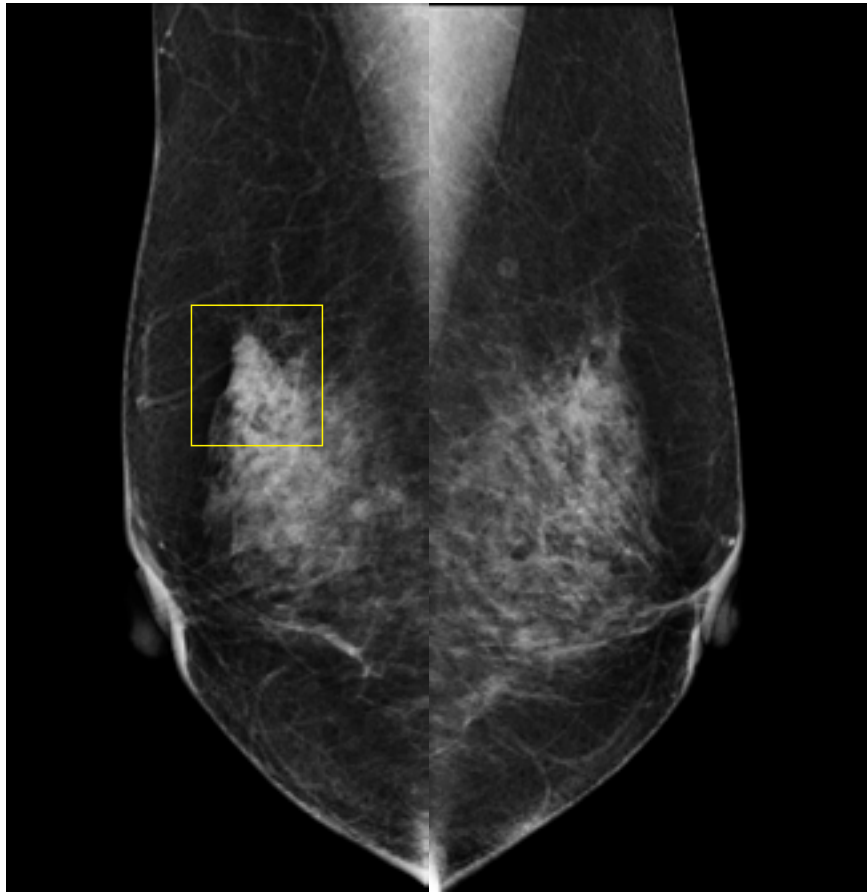
症例 15 (60歳代)



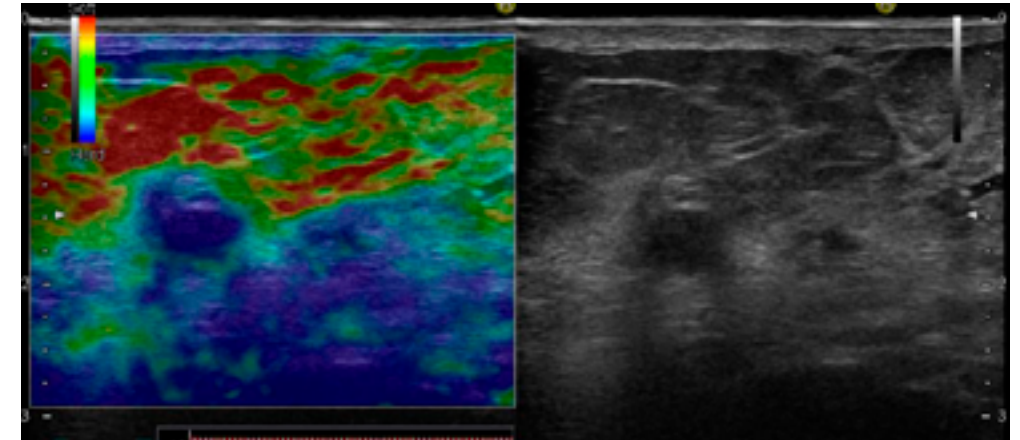
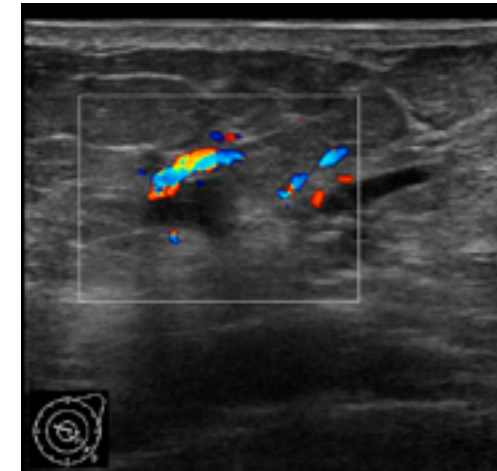
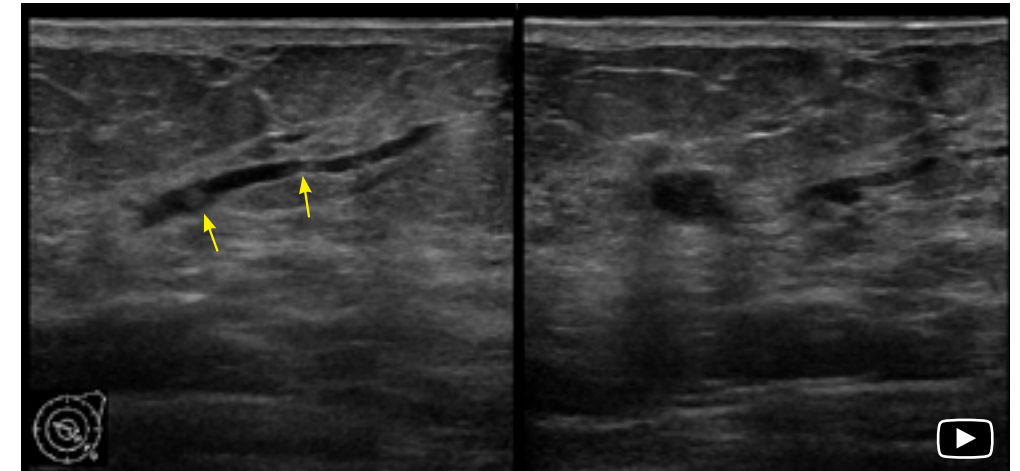
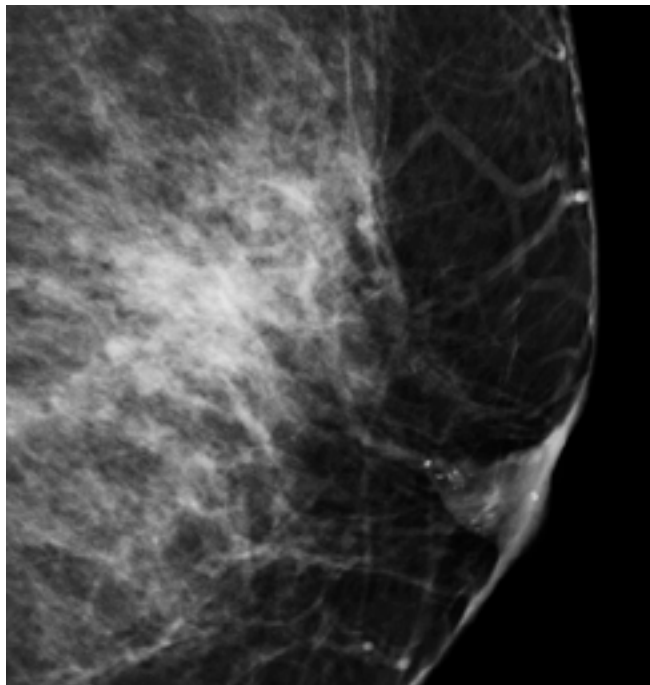
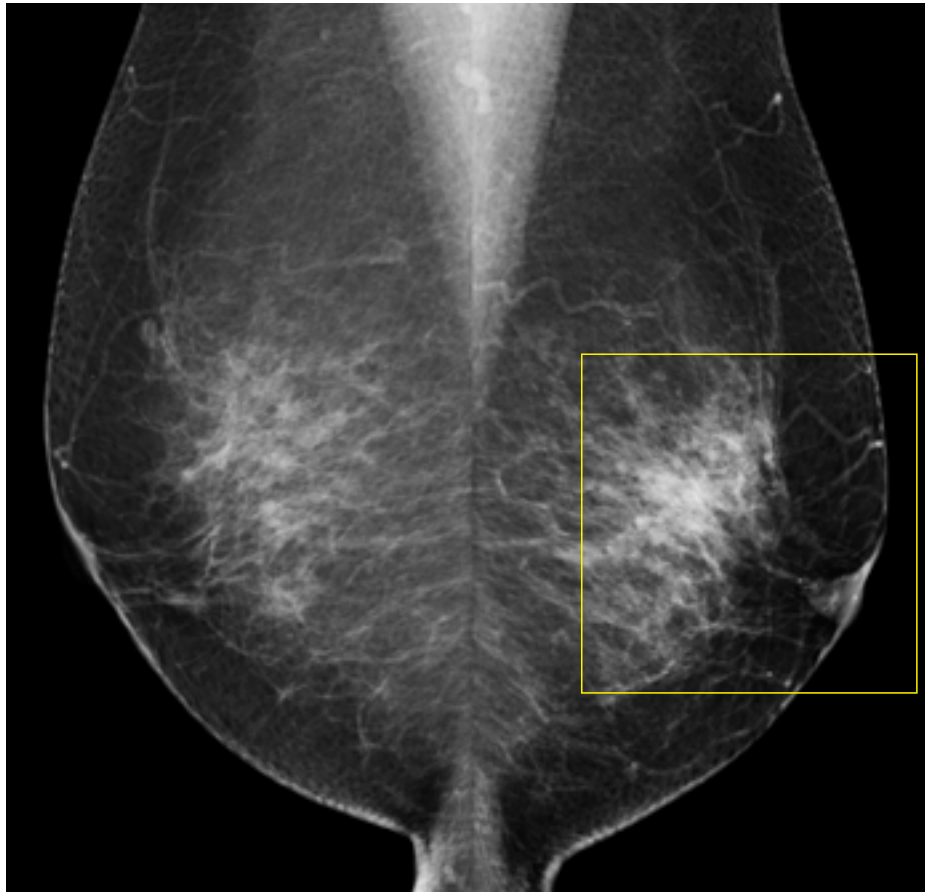
症例 16 (40歳代)



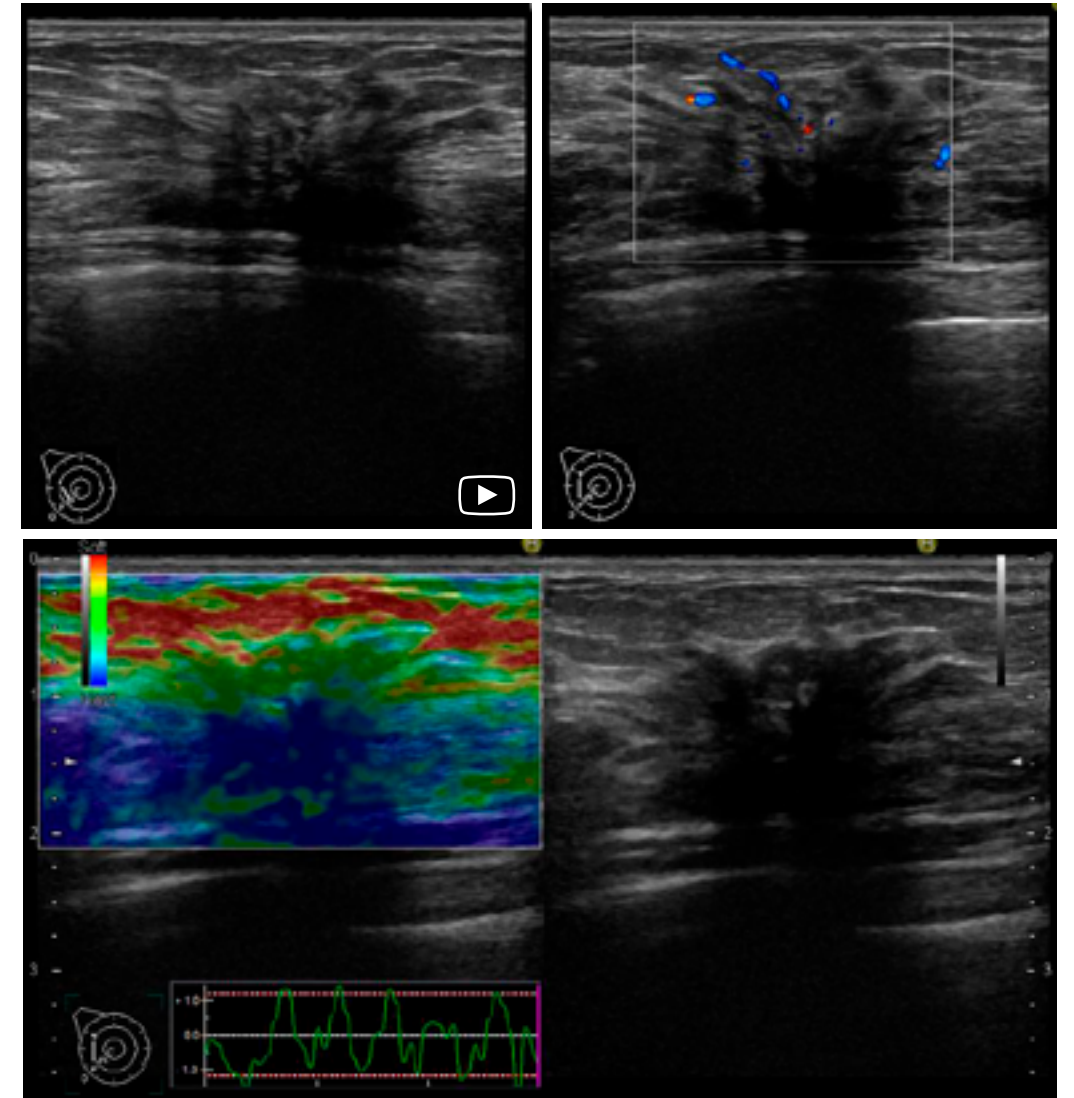
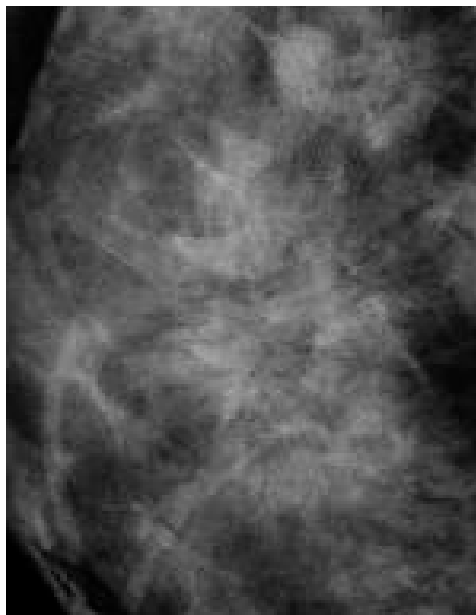
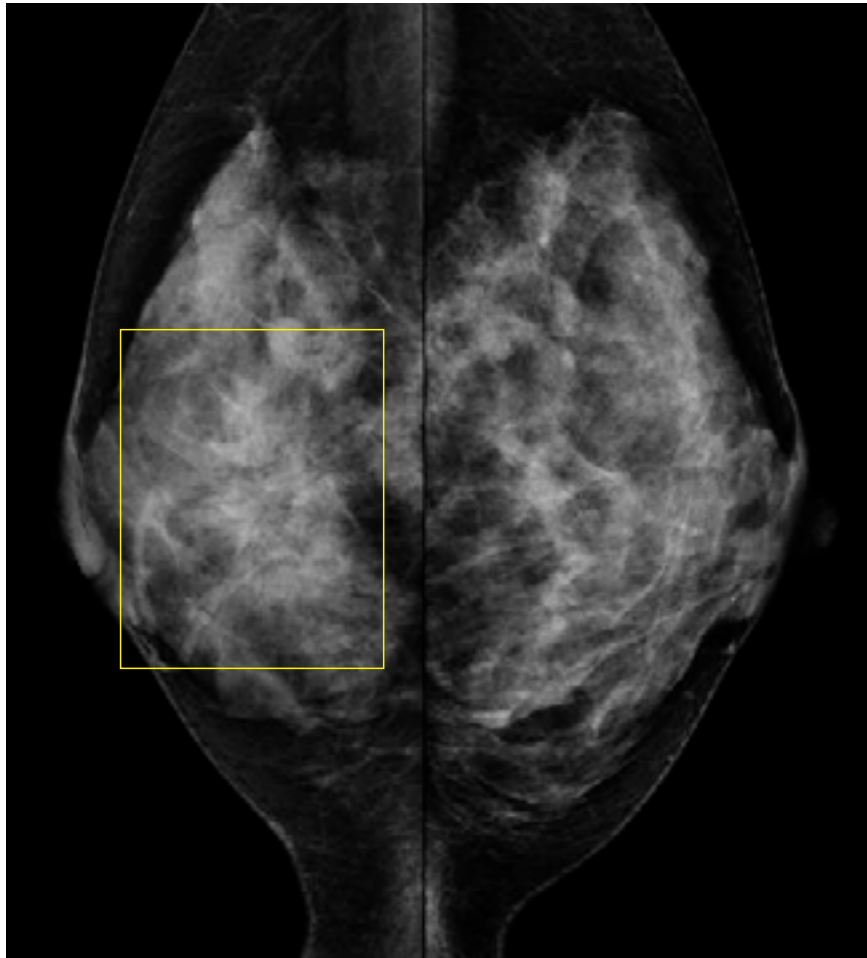
症例 17 (50歳代)



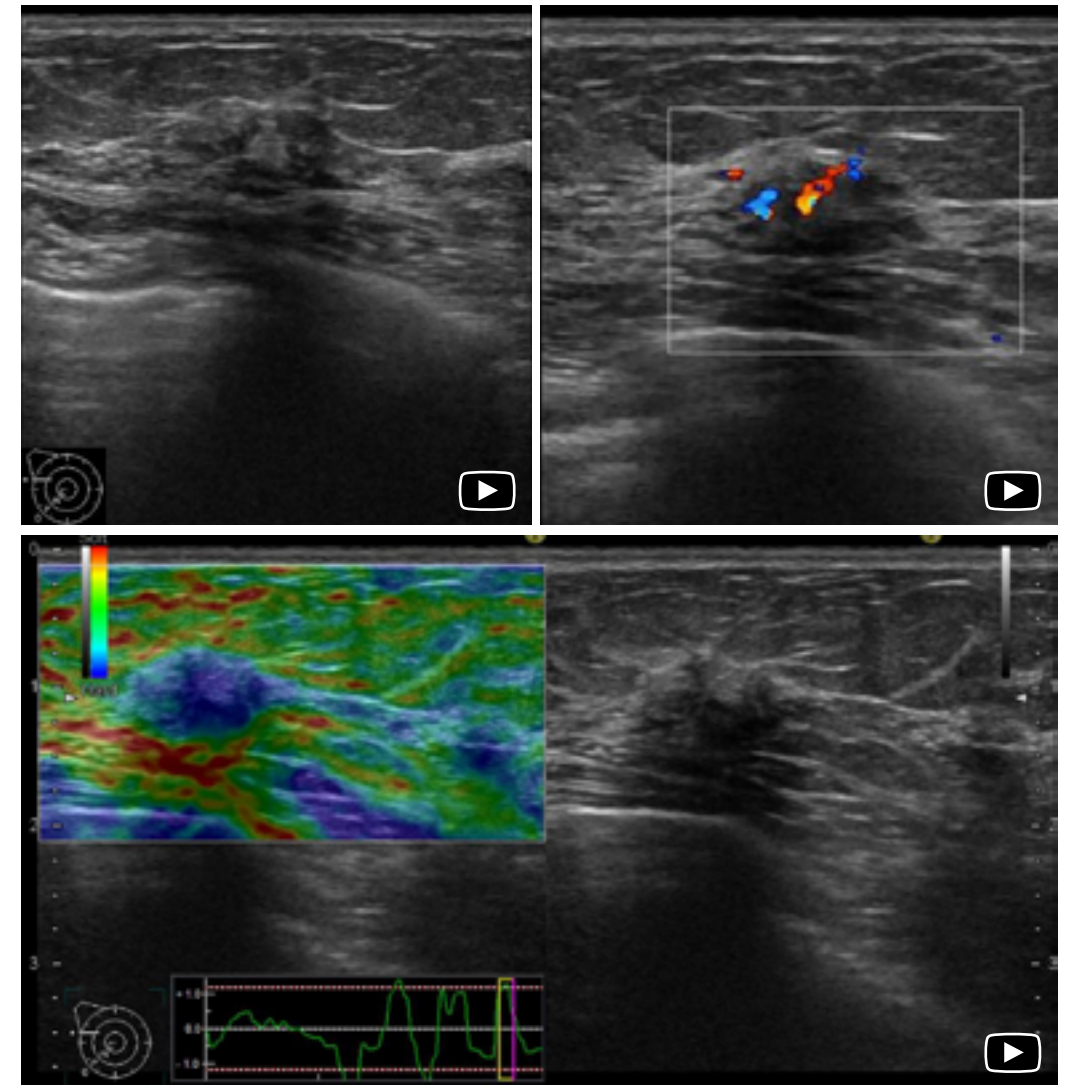
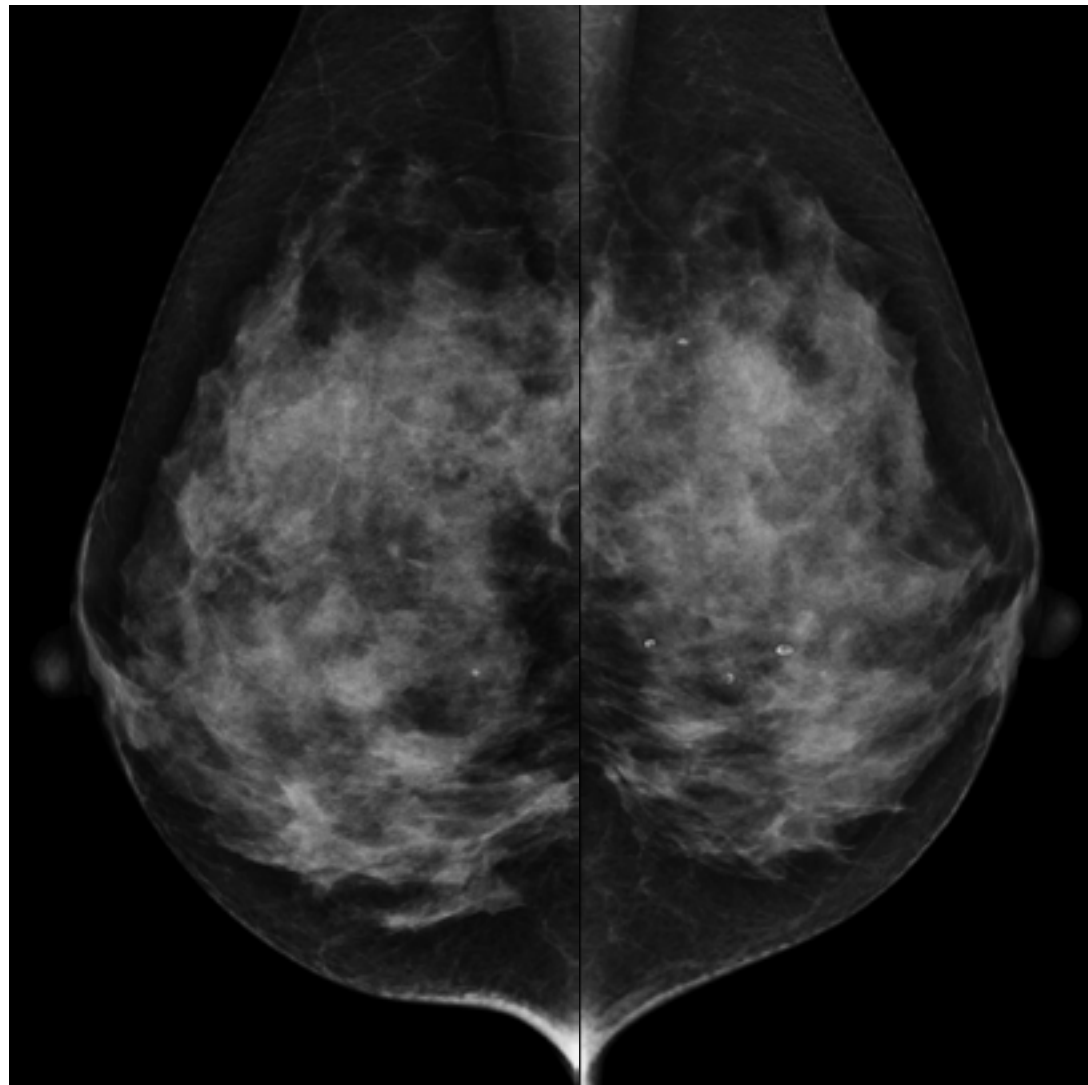
症例 18 (70歳代)



症例 19 (40歳代)



症例 20 (40歳代)



症例 21 (50歳代)

