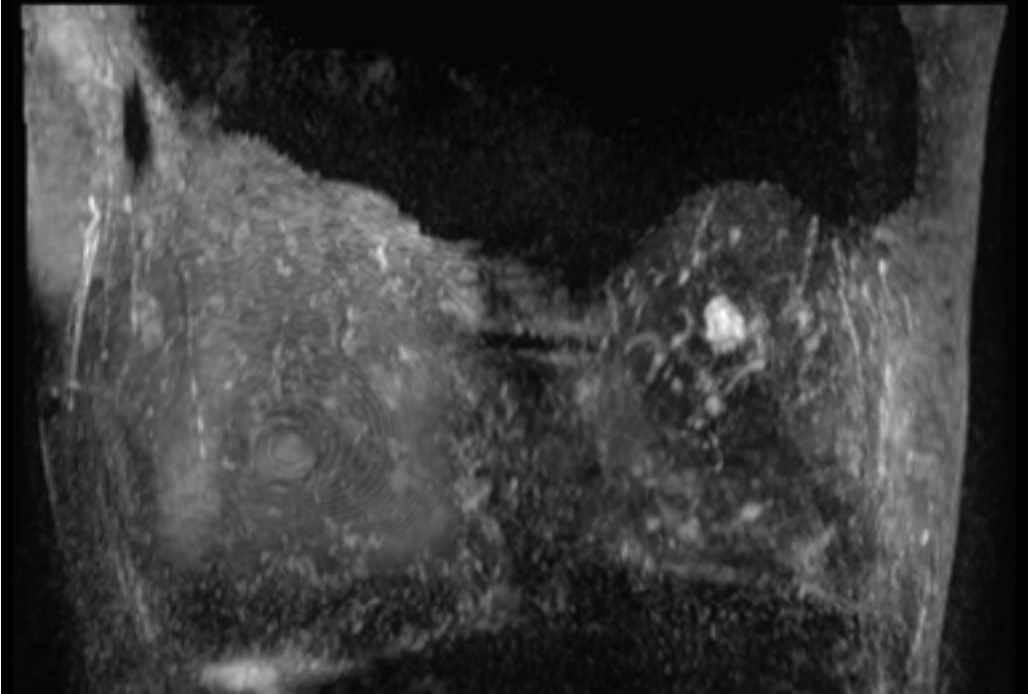
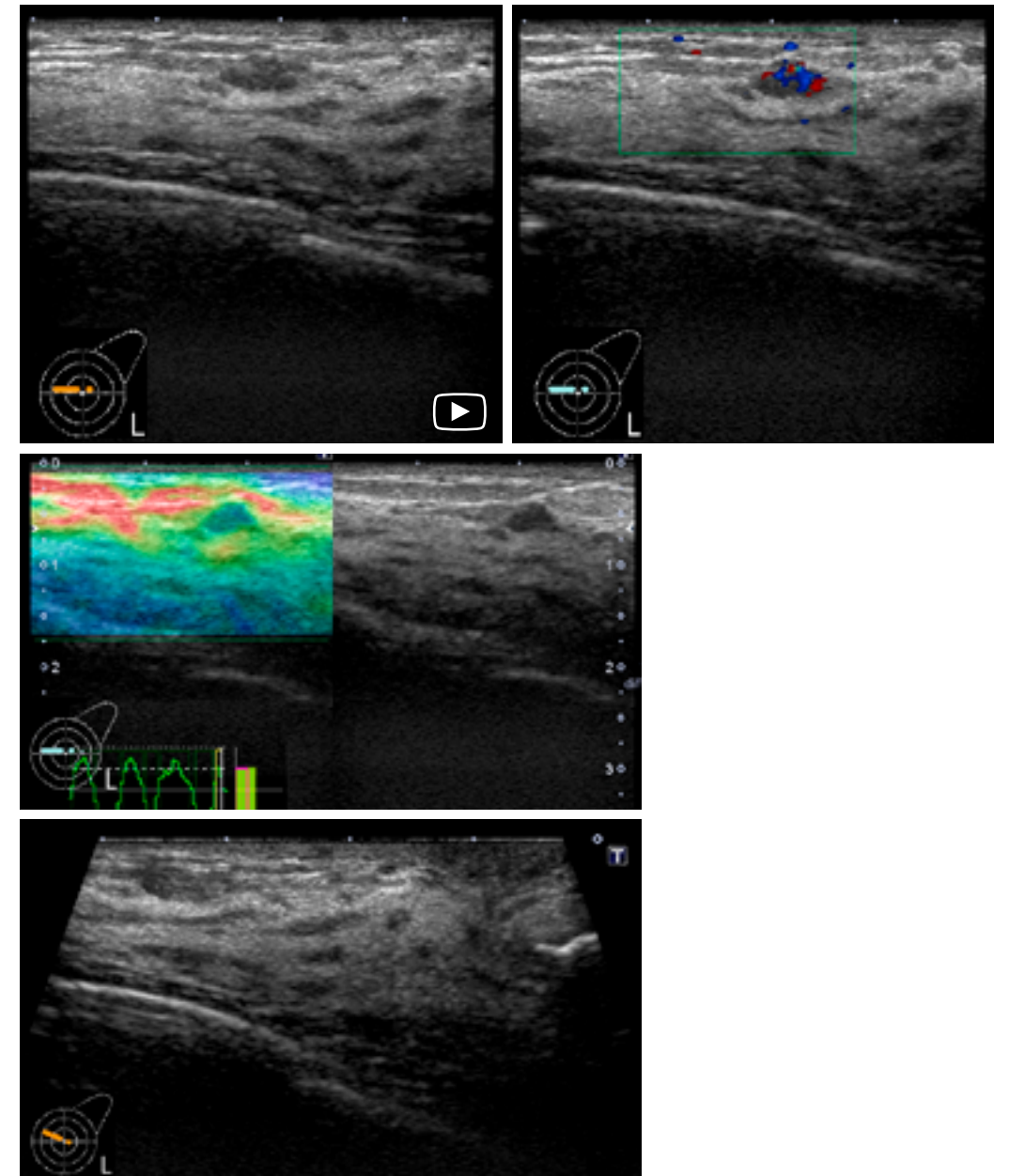
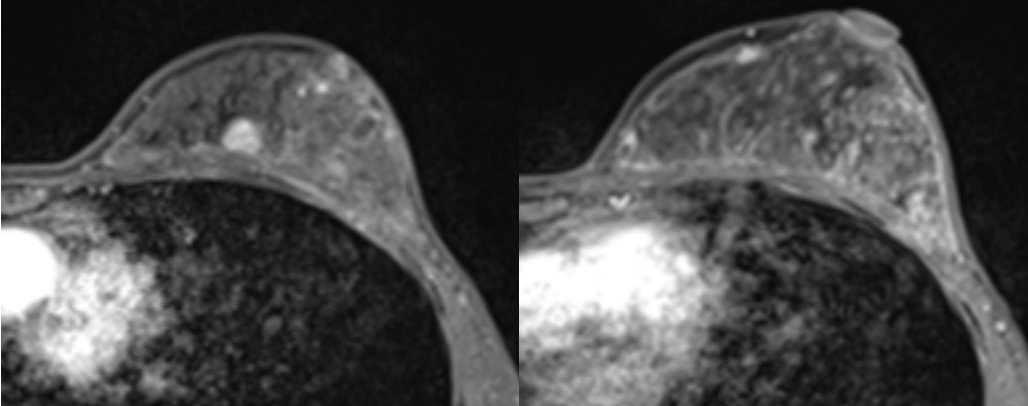


# 症例 1 (40 歳代)

MRI 造影早期 MIP 像

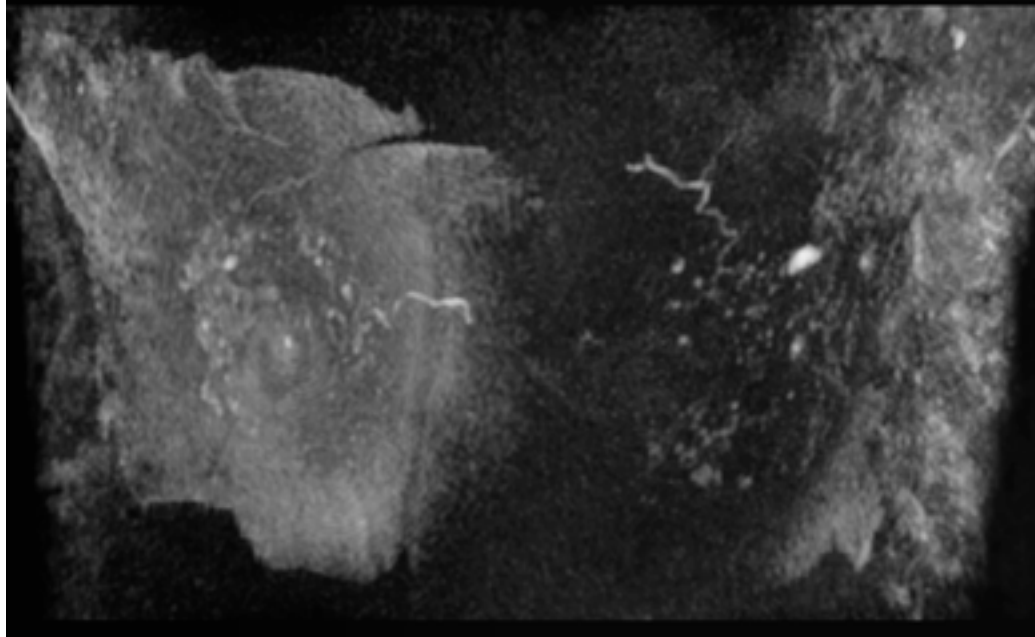


MRI 造影早期横断像

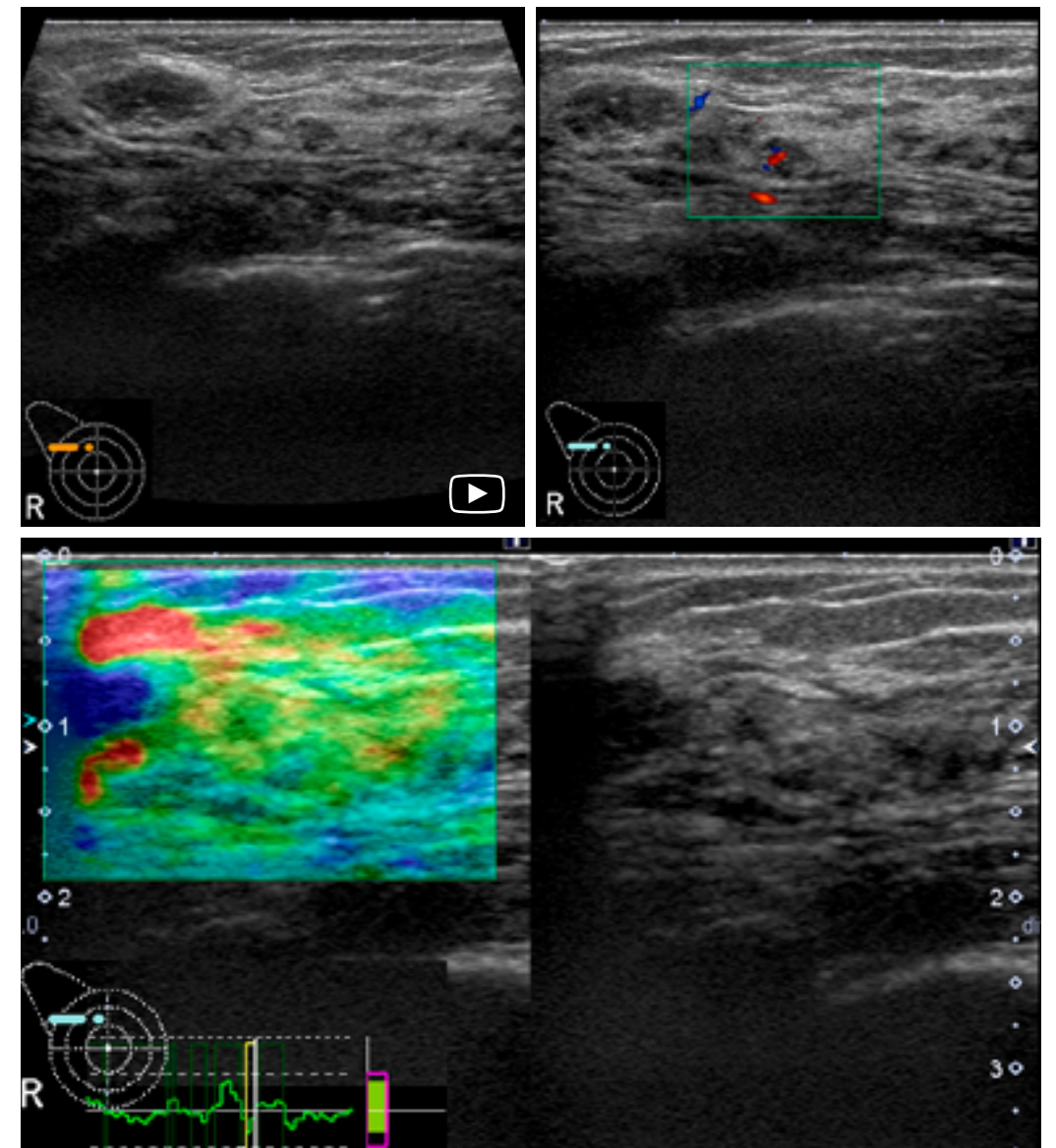
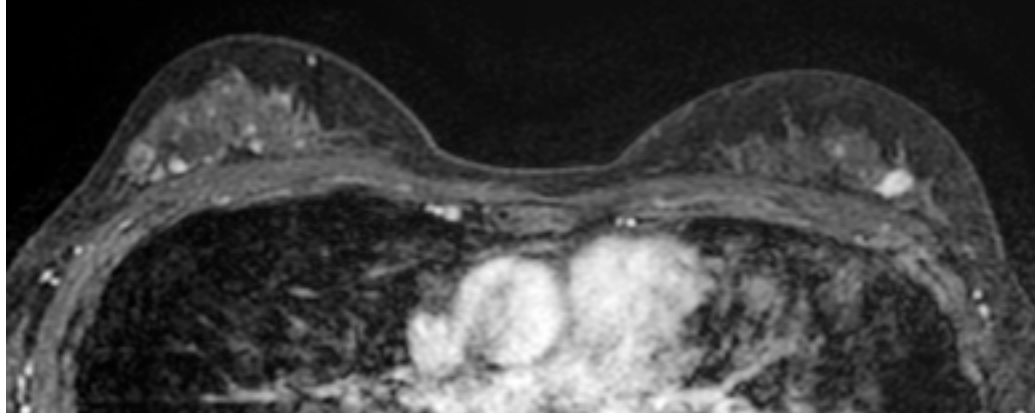


## 症例 2 (50 歳代)

MRI 造影早期 MIP 像

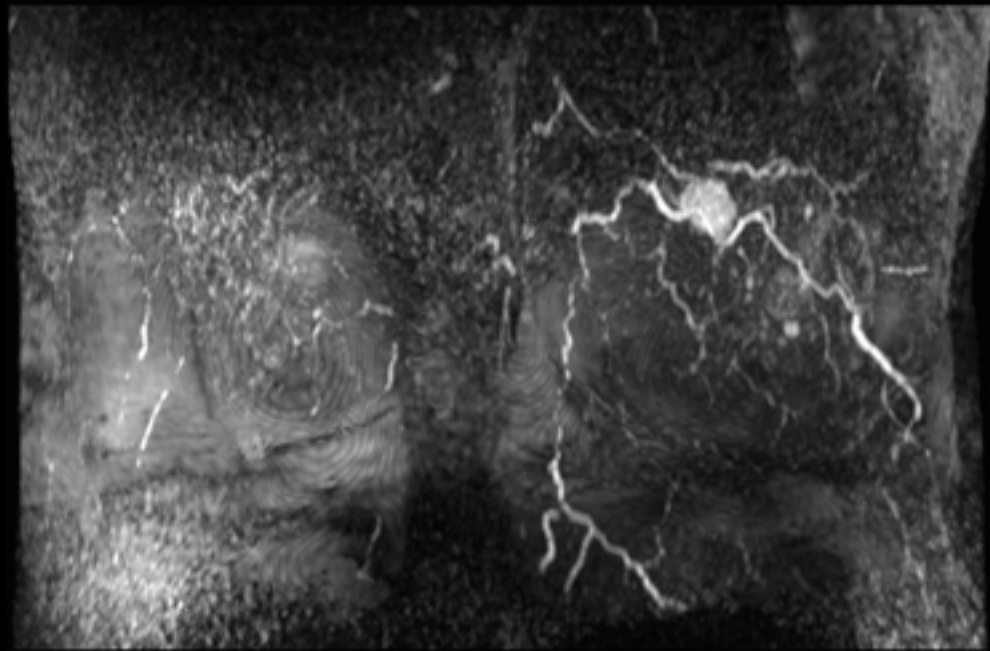


MRI 造影早期横断像

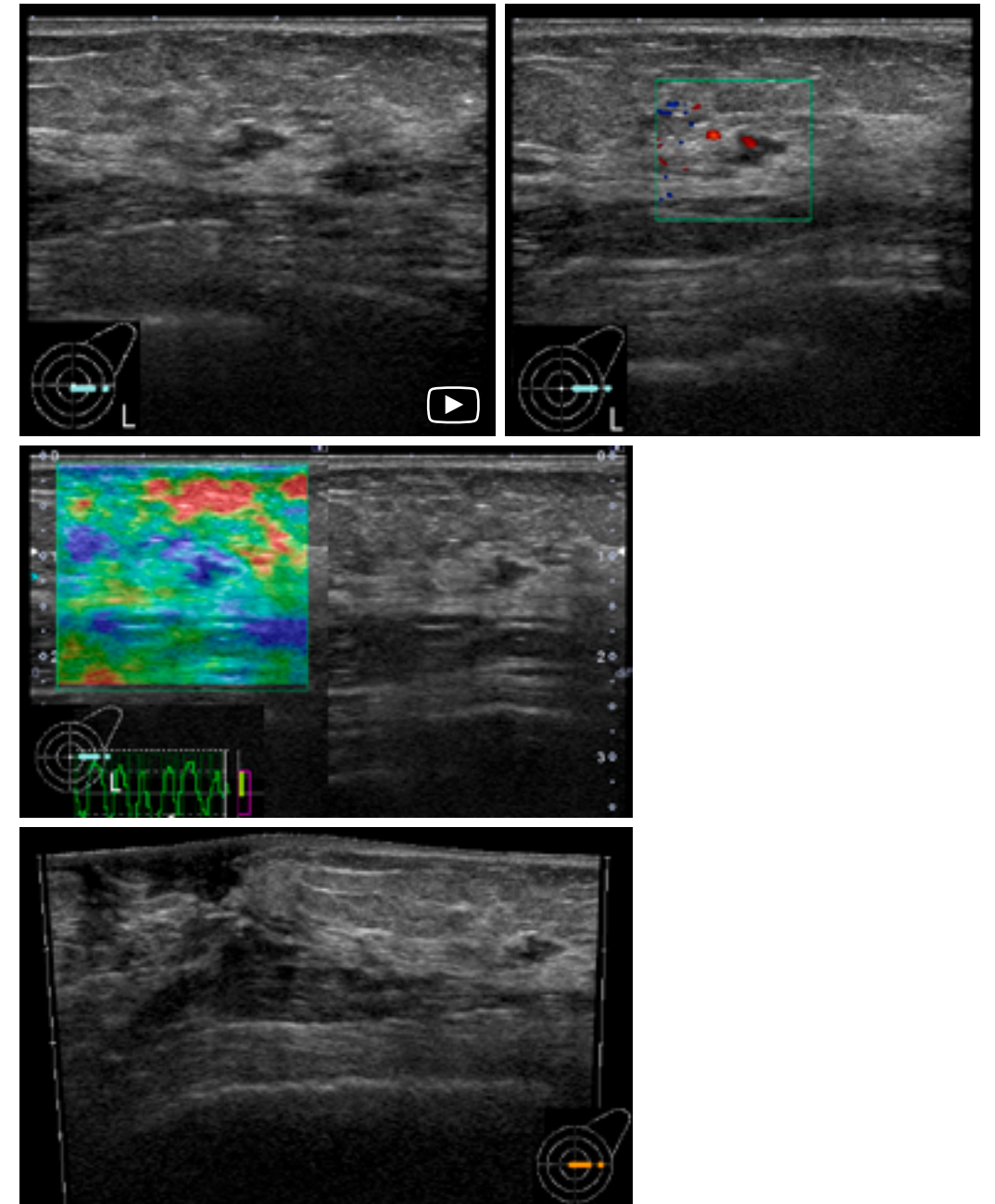
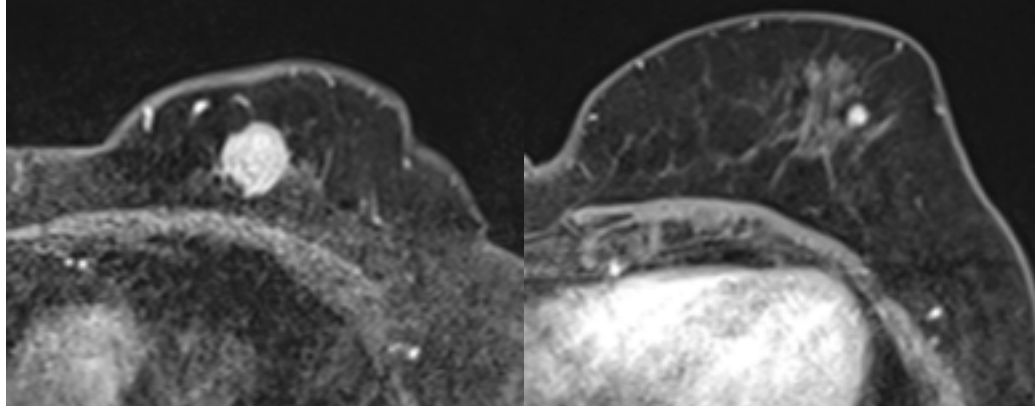


# 症例 3 (70 歳代)

MRI 造影早期 MIP 像

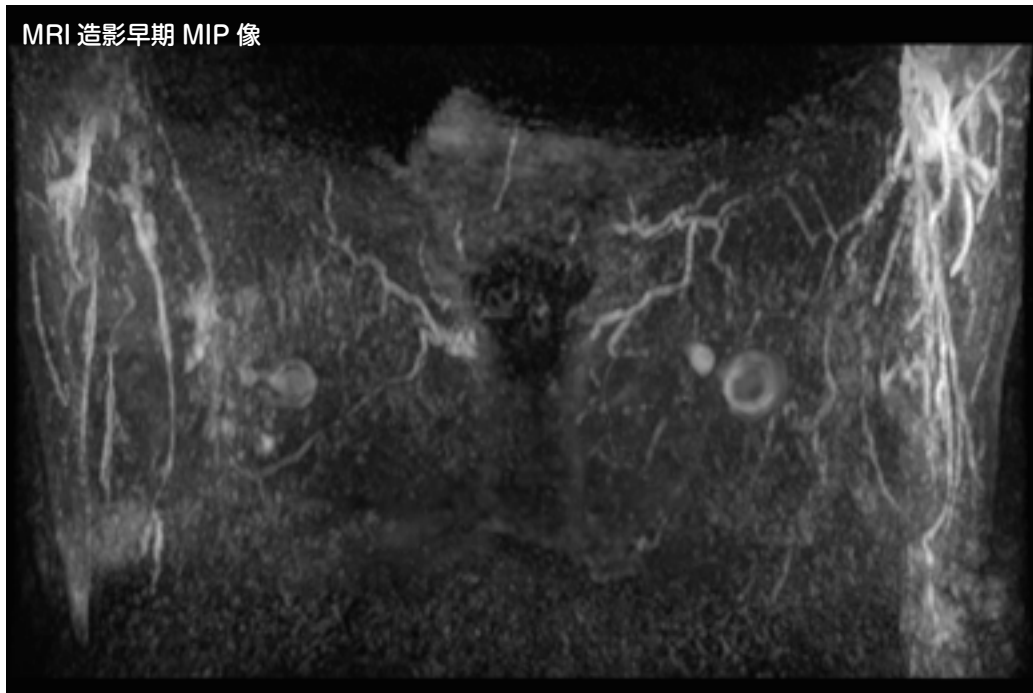


MRI 造影早期横断像

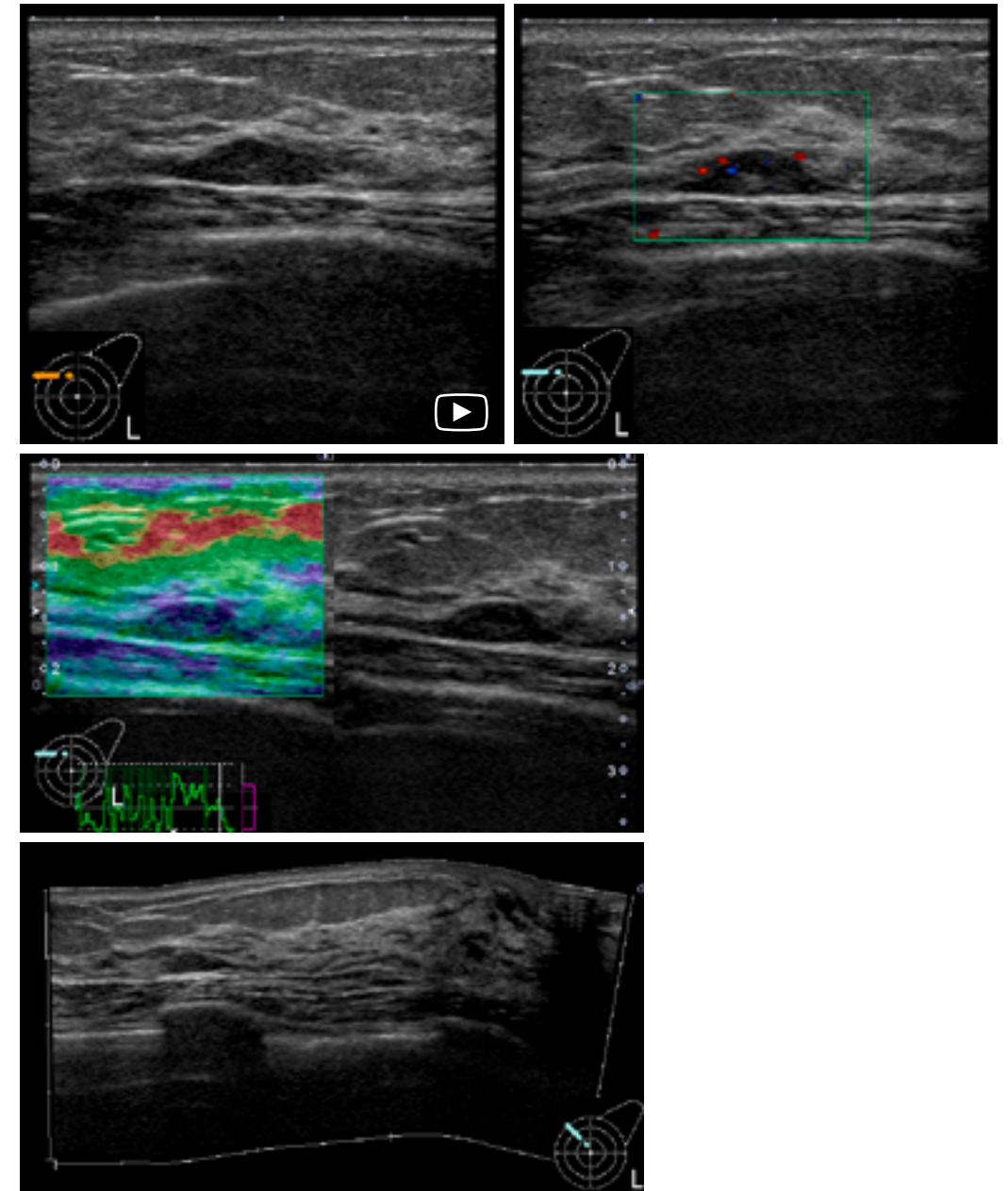
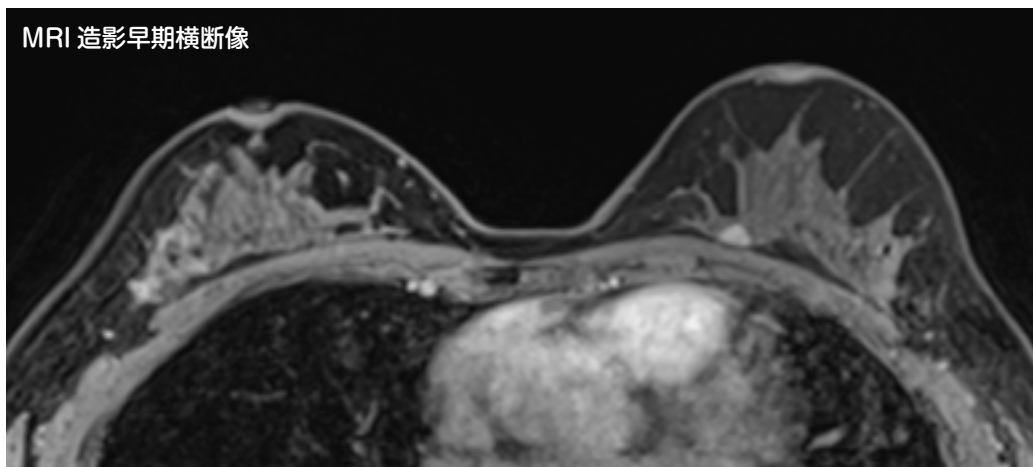


## 症例 4 (40 歳代)

MRI 造影早期 MIP 像

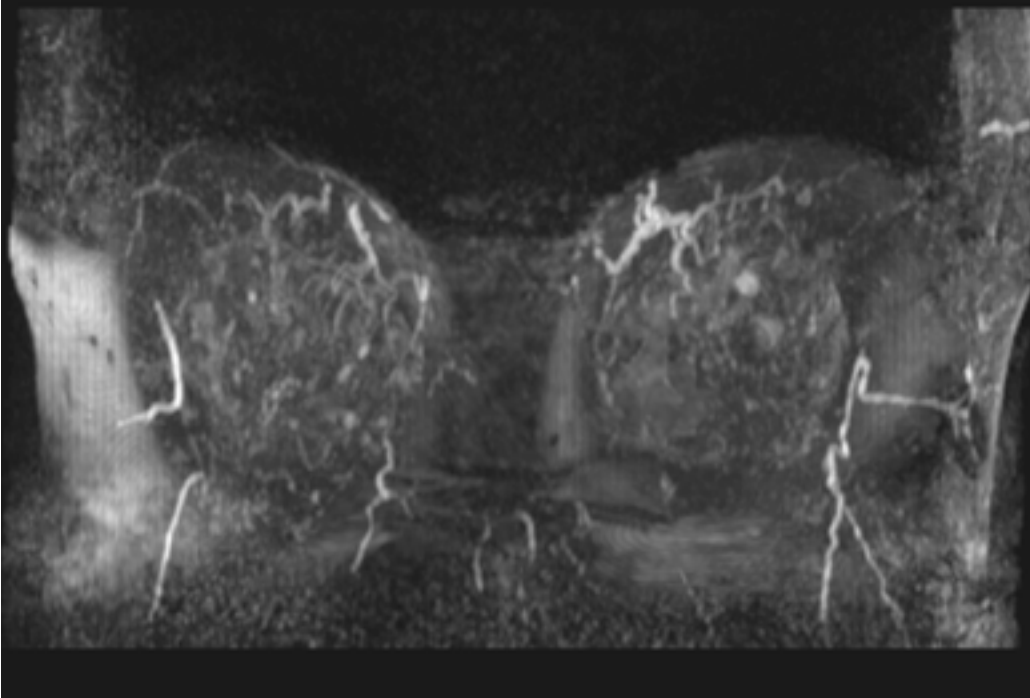


MRI 造影早期横断像

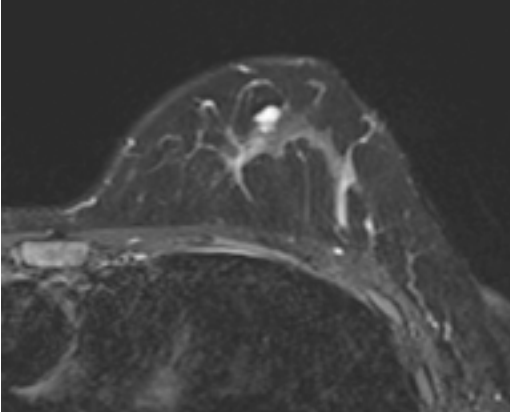


# 症例 5 (50 歳代)

MRI 造影早期 MIP 像



MRI T2 強調横断像



MRI 造影早期横断像

